



NCC Pediatrics Continuity Clinic Curriculum: **Crooked Backs: Scoliosis for General Pediatrics**

Goals & Objectives:

1. Show how to physical screen for scoliosis
2. Calculate a Cobb Angle and Risser Stage from an x-ray
3. Tell your preceptor when to refer a patient with scoliosis.

Pre-Meeting Preparation:

- Read the 2 articles
 - Pediatrics In Review article on Scoliosis
 - Adolescent Idiopathic Scoliosis: Radiologic Decision-Making in the AAFP (May 2002)
- Complete the Scoliosis Crossword Puzzle.

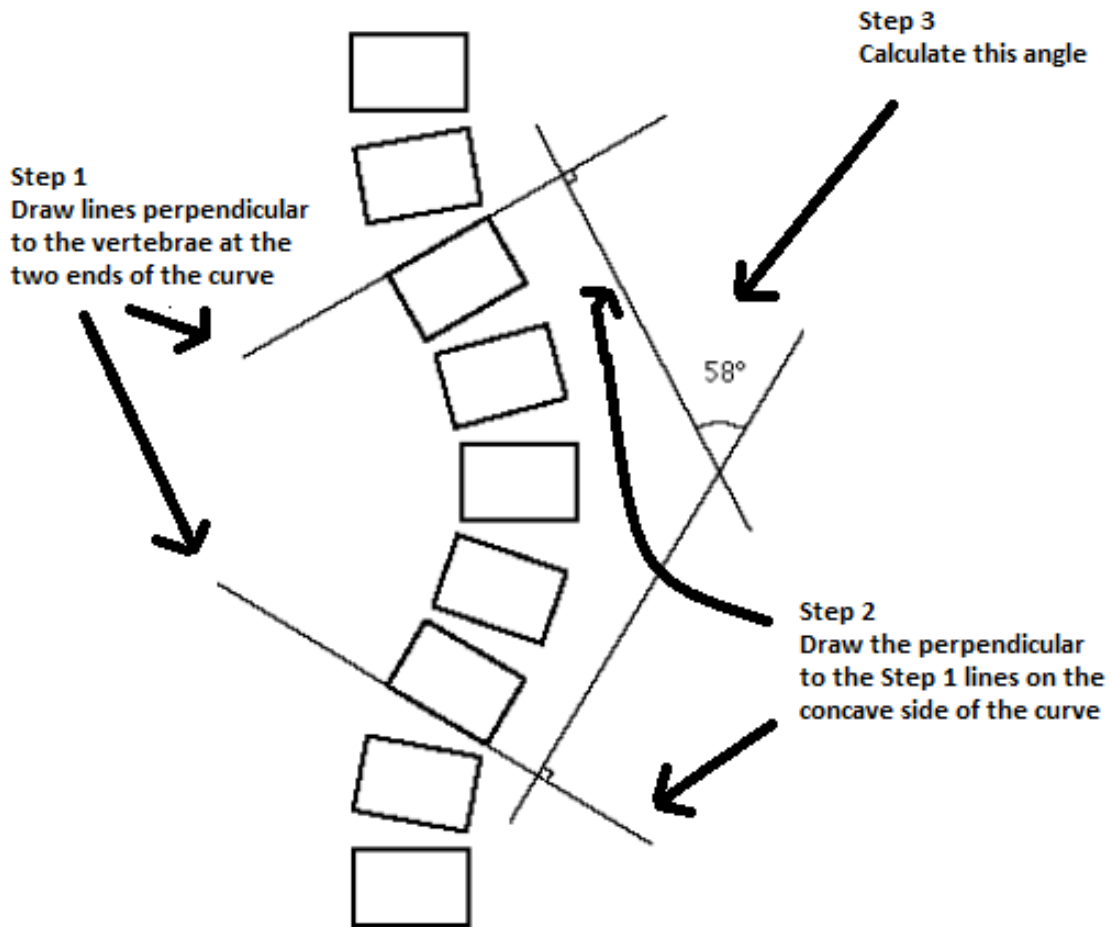
Conference Agenda:

- Answer the questions as a group.
- Demonstrate your technique for calculating Cobb Angles using the images provided

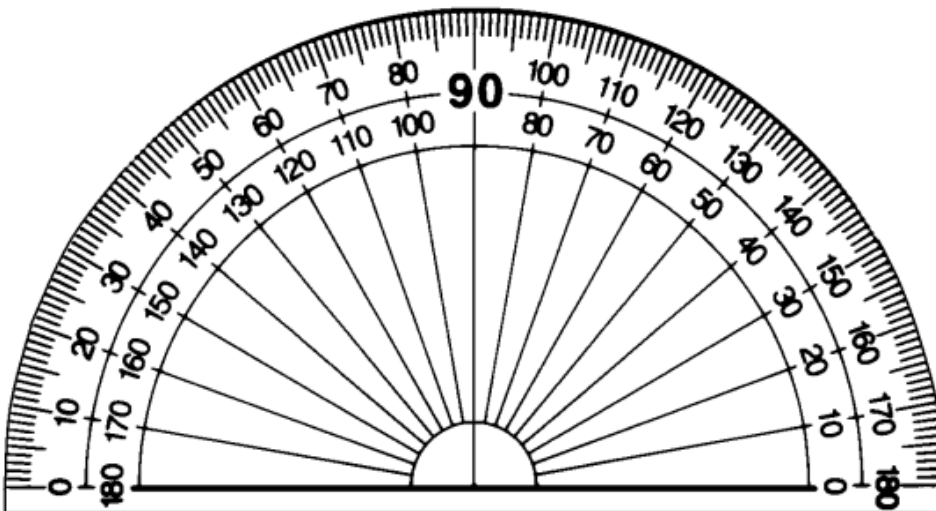
Extra-Credit:

- Use your computer based radiography software to calculate Cobb Angles on a patient
- Find out something about the 'Adams' of the Adams Forward Bend Test or 'Risser'
- Answer the board questions

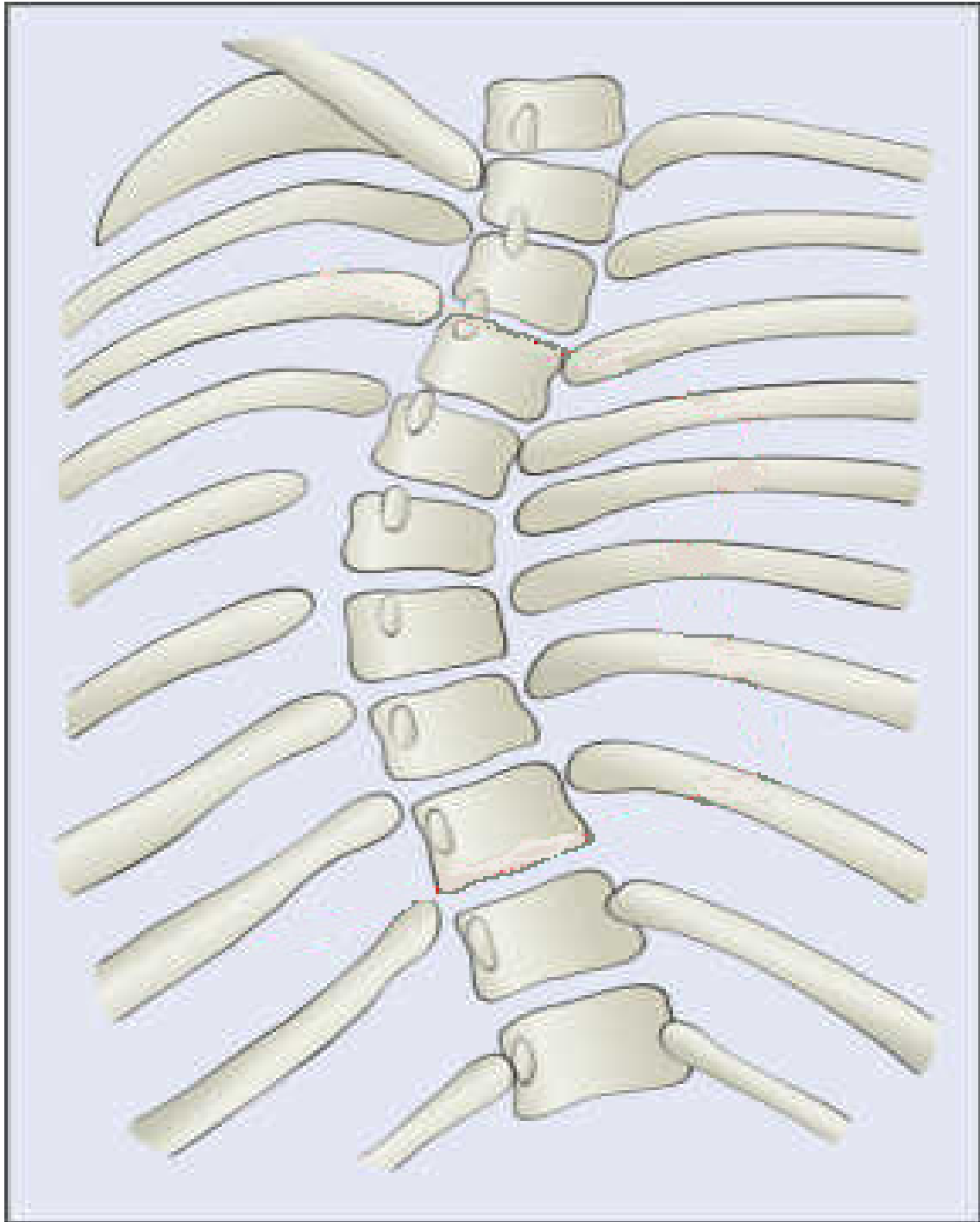
How to Calculate a Cobb Angle

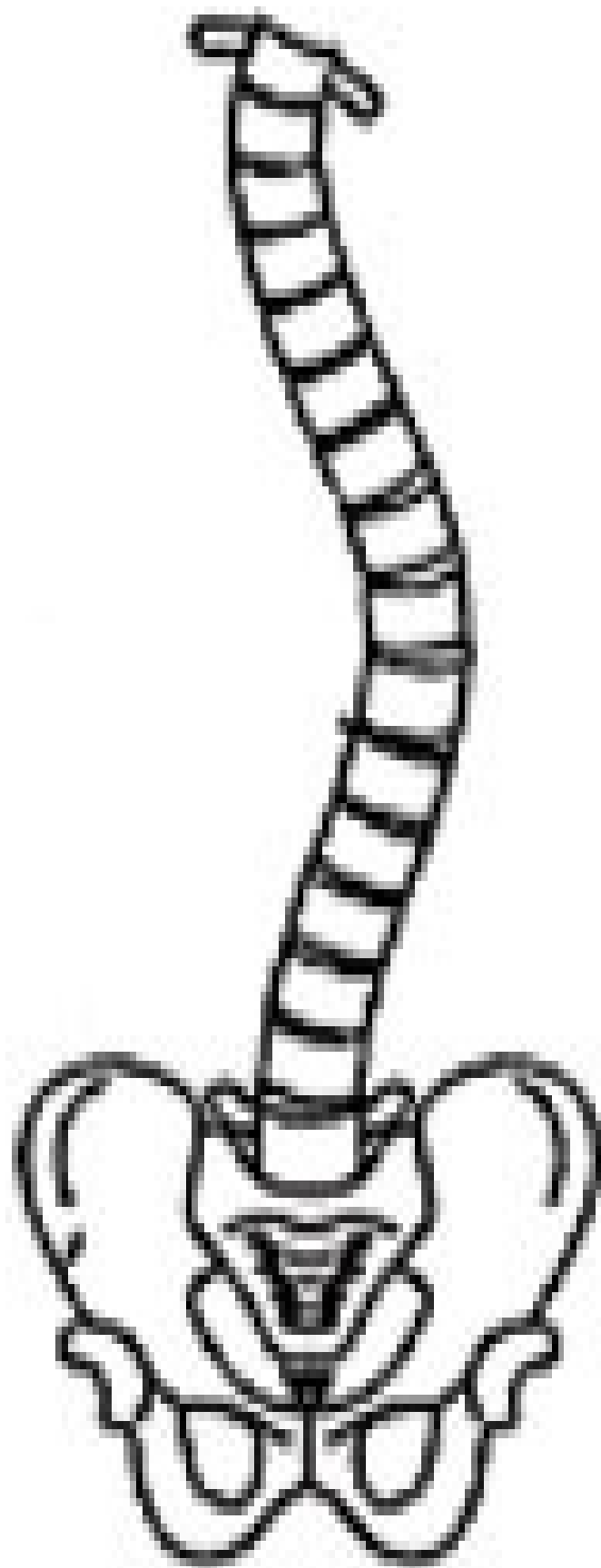

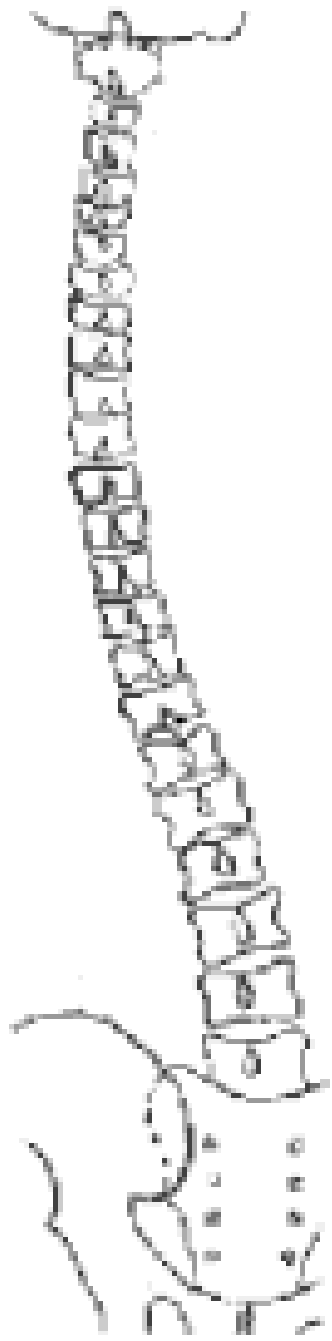
----- cut here for a handy protractor to calculate your angles -----



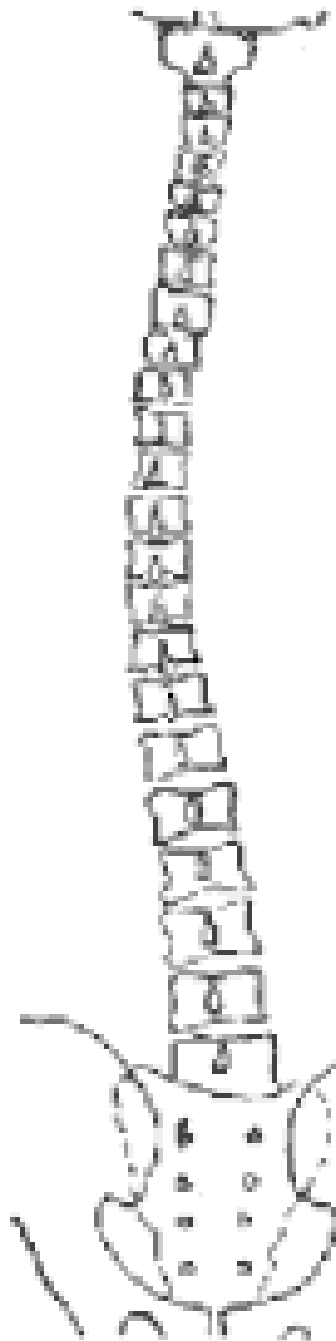
Calculate a Cobb Angle for the following images. Show your work.



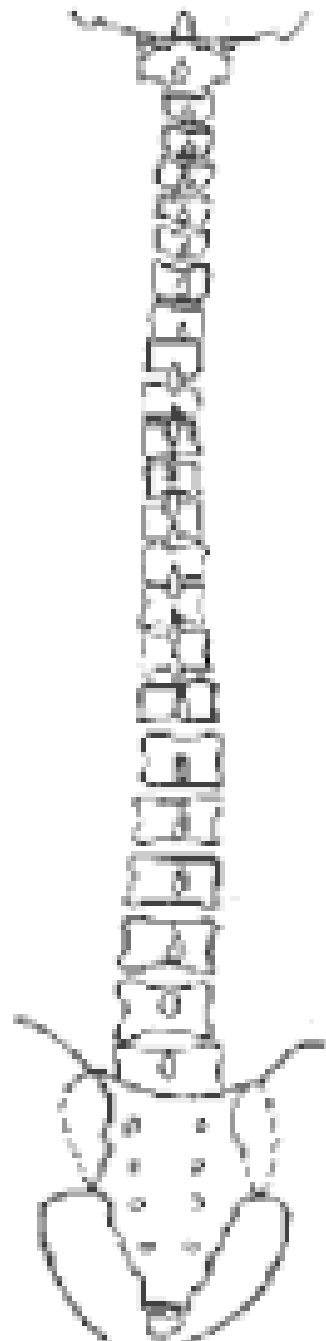




B-02-02




C-02-02



D-02-02

Scoliosis Crossword Puzzle



Across

1. this ataxic disease is associated with non-idiopathic scoliosis
5. a device that measures the curve of the back
6. the Cobb Angle when bracing should first be considered
7. an angle to be calculated on scoliosis films
8. ossification measure used to predict scoliosis progression

Down

1. the Cobb Angle at which surgery is generally recommended
2. anomaly that can cause scoliosis in an infant
3. the scoliometer angle that should prompt scoliosis films
4. compliance with adolescent scoliosis brace therapy, in one study

In Brief

Scoliosis

Jacob J. Rosenberg, MD, FAAP, FRCPC
Vaughan Pediatric Clinic
Woodbridge, Ontario, Canada

Author Disclosure

Drs Rosenberg and Adam have disclosed no financial relationships relevant to this In Brief. This commentary does not contain a discussion of an unapproved/investigative use of a commercial product/device.

Screening for Idiopathic Scoliosis in Adolescents. Richards S, Vitale M. *J Bone Joint Surg Am.* 2008;90:195–198

Screening for Adolescent Idiopathic Scoliosis. Policy Statement. US Preventive Services Task Force. *JAMA.* 1993;269:2664–2666

Scoliosis is a lateral curvature of the spine. Although it can result from a variety of causes, more than 60% of all cases are considered idiopathic. Eighty percent of idiopathic scoliosis occurs in adolescents, while infantile scoliosis (ages 0 to 3 y) and juvenile scoliosis account for 1% and 12% to 21% of cases, respectively. Nonidiopathic scoliosis, about one third of all cases, is associated with underlying neurologic disorders (cerebral palsy, myelomeningocele, tethered cord syndrome, spinal muscular atrophy, syringomyelia, muscular dystrophy, Friedrich ataxia, Riley-Day syndrome), musculoskeletal disorders (leg length discrepancy, developmental dysplasia of the hip, osteogenesis imperfecta, Klippel-Feil syndrome), and connective tissue

disorders (Marfan syndrome, Ehlers-Danlos syndrome, homocystinuria).

The primary tasks for the clinician when scoliosis is diagnosed are to: 1) determine whether the condition is idiopathic or if there is an underlying cause and 2) measure the curvature and ascertain whether it is likely to worsen. The major factors influencing the progression of the curve are sex, potential for future growth, and the magnitude of the curve at the time of diagnosis. Mild curvature of the spine (10 to 30 degrees) occurs equally in males and females, but 80% to 90% of patients who have curves greater than 30 degrees are females. The more potential for growth, the greater is the risk that the curvature will worsen. Growth potential can be determined by assessing Sexual Maturity Rating (SMR) on physical examination and Risser grading on radiography. Risser grading is a measurement of the ossification of the iliac apophysis: 0 is no ossification, grade 1 is up to 25% ossification, grade 2 is 26% to 50% ossification, grade 3 is 51% to 75% ossification, grade 4 is 76% to 99% ossification, and grade 5 is complete ossification. The lower the SMR stage and Risser grade, the greater is the risk that the scoliosis will progress. The magnitude of the curve is measured on radiograph by determining the Cobb angle: an angle derived from the positions of the most tilted vertebrae above and below the apex of the curve. The greater the Cobb angle, the higher is the risk of progression.

The adverse effects of progressive scoliosis include cosmetic deformity with its potential for social and psychological consequences both during childhood and adulthood; the financial costs of therapy; and although the associa-

tion is controversial before adulthood, the development of chronic back pain. With extreme curvatures (possibly >50 degrees, certainly >75 degrees), scoliosis can lead to respiratory compromise as well. Because scoliosis often occurs without symptoms, the concept of universal screening during the adolescent years has been advocated, both through screening in school and by routine examination during health supervision visits. School-based screening was begun in 1984 and endorsed by the American Academy of Orthopaedic Surgeons (AAOS), with the underlying conviction that early detection of scoliosis when the deformity may have gone unnoticed can lead to nonoperative treatment that can have a positive impact on long-term outcome.

The primary screening test is the physical examination, which includes visual inspection of the back with the patient standing upright and the Adams forward bending test. With this test, the patient stands with feet together and knees straight and slowly bends forward from the waist, as if to touch the toes, allowing the arms to hang with palms touching. The examiner, with eyes level with the back, looks for asymmetry of one scapula or one side of the rib cage or the paraspinal muscles more prominent than the other. A scoliometer, which is a variation of a carpenter's level, is useful for quantifying the degree of chest deformity, both in the initial evaluation and in following progression of the curve. The degree measurements noted on the scoliometer are not equivalent to the degrees of the Cobb angle. Many clinicians use a scoliometer measurement of 6 to 7 degrees or more as an indication for obtaining radiographs. If scoliosis is

suspected based on physical examination findings, a radiograph of the back should be considered to measure the degree of curvature (ie, the Cobb angle) and the Risser grade.

Screening is not without its difficulties. Almost one third of patients who are identified as having scoliosis by school screening programs are found on further investigation to have no abnormality. In 1996, the United States Preventive Services Task Force (USPSTF) concluded that evidence was insufficient to make a recommendation for or against screening. However, the USPSTF changed its position in 2004, recommending against routine screening of asymptomatic adolescents for idiopathic scoliosis because of the low predictive value, the relatively small percentage of children whose curves progress, and the possibility of screening leading to unnecessary treatment, including the use of braces. This change in position was influenced by a study in the Netherlands that showed no significant reduction in the need for scoliosis surgery attributable to screening. Patients detected by screening were significantly younger at diagnosis than patients who were detected otherwise. Further, patients detected by routine screening had additional years of concern about their scoliosis, and although they were more likely to be treated with bracing, they did not have better final outcomes.

The USPSTF urges that instead of routine screening, clinicians should evaluate scoliosis when it presents as a symptom or is found incidentally. If scoliosis screening is undertaken, the AAOS, Scoliosis Research Society, Pedi-

atric Orthopaedic Society of North America, and the American Academy of Pediatrics (AAP) agree that girls should be screened twice, at ages 10 and 12 years, and boys once at 13 or 14 years. The AAP *Bright Futures* recommends examination of the back at adolescent health supervision visits, which can include the forward bend test.

Treatment of scoliosis begins with a focused history and physical examination, looking for an underlying cause of the curvature. In cases of idiopathic scoliosis, intervention is aimed at preventing, or at least minimizing, cosmetic deformity, respiratory compromise, and significant pain. Exercise therapy has been advocated, but there is no evidence that it reverses or even slows the progression of curvature. Bracing uses mechanical force to straighten the spine, but whether it can reliably prevent progression of the curve is less certain. One of the major issues with brace therapy is the difficulty that adolescents have in adhering to the regimen, with one study showing only 15% compliance and reporting that most patients wore their braces only 65% of the recommended time. In general, bracing can be considered for curves between 20 and 40 degrees in patients who still have significant growth potential. With skeletal maturation, as evidenced by a high Risser grading, such curves should not need intervention. For curves greater than 40 degrees, surgery using spinal fusion and any of a variety of instrumentation techniques is the generally recommended treatment.

Comment: Two controversial questions for the pediatrician surrounding scoliosis are whether to screen routinely, and in a child complaining of backache who has a curve, how likely is scoliosis an explanation for the pain. The problem with routine screening is that it is poorly predictive of patients who will ultimately benefit from intervention. Most children identified by routine screening in early adolescence either do not have scoliosis or have curves that require no treatment. These children will more than likely be irradiated at least once, if not serially, and will face anxiety over whether they will become "deformed" or need surgery. The argument for routine screening becomes more difficult in the absence of solid evidence that early bracing really retards curve progression. If it does not, curves destined to warrant surgery will progress despite early screening.

As for back pain and scoliosis, although long-term follow-up studies support the association of scoliosis and chronic back pain in adulthood, the evidence among pediatric patients is less clear. When a child or adolescent who has scoliosis complains of back pain, consideration should be given to the possibility of the scoliosis not being idiopathic, an underlying musculoskeletal or neurologic cause producing the pain, or the back pain being unrelated to the scoliosis. Who said practicing medicine is easy?

Henry M. Adam, MD
Editor, *In Brief*

Parent Resources from the AAP at HealthyChildren.org

The reader is likely to find material to share with parents that is relevant to this article by visiting this link: <http://www.healthychildren.org/english/health-issues/conditions/orthopedic/pages/scoliosis.aspx>.

Adolescent Idiopathic Scoliosis: Radiologic Decision-Making

K. ALLEN GREINER, M.D., M.P.H., University of Kansas Medical Center, Kansas City, Kansas

Adolescent onset of severe idiopathic scoliosis has traditionally been evaluated using standing posteroanterior radiographs of the full spine to assess lateral curvature with the Cobb method. The most tilted vertebral bodies above and below the apex of the spinal curve are used to create intersecting lines that give the curve degree. This definition is controversial, and patients do not exhibit clinically significant respiratory symptoms with idiopathic scoliosis until their curves are 60 to 100 degrees. There is no difference in the prevalence of back pain or mortality between patients with untreated adolescent idiopathic scoliosis and the general population. Therefore, many patients referred to physicians for evaluation of scoliosis do not need radiographic evaluation, back examinations, or treatment. Consensus recommendations for population screening, evaluation, and treatment of this disorder by medical organizations vary widely. Recent studies cast doubt on the clinical value of school-based screening programs. (*Am Fam Physician* 2002;65:1817-22. Copyright© 2002 American Academy of Family Physicians.)

Coordinators of this series are Mark Meyer, M.D., University of Kansas School of Medicine, Kansas City, Kan., and Walter Forred, M.D., University of Missouri-Kansas City School of Medicine, Kansas City, Mo.

Adolescent idiopathic scoliosis is lateral and rotational spinal curvature in the absence of associated congenital or neurologic abnormalities. Longitudinal studies^{1,2} estimate the prevalence of idiopathic scoliosis as 2 percent of the adolescent population, using a definition of a spinal curve greater than 10 degrees.³ However, clinically significant curves in the range of 40 to 100 degrees are rare. Controversy surrounds clinical recommendations for evaluating and managing patients with a wide range of curve sizes. Recent debate has centered on the value of school-based screening programs.⁴

School-Based Screening

School-based scoliosis screening programs are currently mandated in 26 states, with many other states having voluntary programs. Several studies^{1,5,6} and the 1996 U.S. Preventive Services Task Force (USPSTF) Report⁷ question the value and cost-effectiveness of these programs. Few children referred for medical evaluation from these programs receive any form of therapy.⁸ Furthermore, the long-term health outcomes for treated versus untreated patients with scoliosis have not been well studied, making it difficult to

determine the health impact of these screening programs. Patients with severe curves are not difficult to diagnose. Although some advocates still recommend school-based screening of adolescents, there is no evidence to support these programs. The American Academy of Pediatrics recommends screening at physician visits. The USPSTF and the Canadian Task Force on the Periodic Health Examination state that insufficient evidence exists to support universal school-based screening. Radiographic decision-making skills will help primary care physicians evaluate severe scoliosis accurately.

Etiology

The etiology of adolescent idiopathic scoliosis is believed to be multifactorial, including genetic factors. One study⁹ showed a 73 percent phenotypic concordance of scoliosis in monozygotic twins. Eleven percent of first-degree relatives of patients with scoliosis are affected. Inheritance of scoliosis varies, and no single pattern of genetic transmission has been accepted. The physiologic causes of scoliosis have not been elucidated. Muscular, nervous system, hormonal, and connective tissue defects have been noted in subgroups of patients with scoliosis, but these abnor-

The editors of AFP welcome the submission of manuscripts for the Radiologic Decision-Making series. Send submissions to Jay Siwek, M.D., following the guidelines provided in "Information for Authors."

A patient's skeletal maturity can determine the risk of progression of more severe scoliosis curves.

malities may be a result of the disorder rather than a cause.¹⁰

Natural History

Studies¹¹⁻¹³ of adolescent-onset scoliosis have demonstrated that patients with scoliosis show minimal progression in the magnitude of the curve in adulthood if the curve is less than 30 degrees at skeletal maturity. Although curves in different regions of the spine progress differently, curves measuring 40 to 50 degrees at skeletal maturity progress an average of 10 to 15 degrees during a normal lifetime, while curves measuring greater than 50 degrees at skeletal maturity progress at a rate of approximately 1 to 2 degrees per year.¹¹ Because of the controversy surrounding ideal treatment strategies for patients with moderate curves, estimation of curve progression can aid in clinical management and counseling patients' families about prognoses.

Estimation of skeletal maturity can be determined by assessing the epiphyseal status on wrist radiographs, the Risser sign, Tanner stages, progressive sitting and standing height measurements, and age at menarche.

Risser sign is defined by the amount of calcification present in the iliac apophysis and measures the progressive ossification from anterolaterally to posteromedially. A Risser grade of 1 signifies up to 25 percent ossifica-

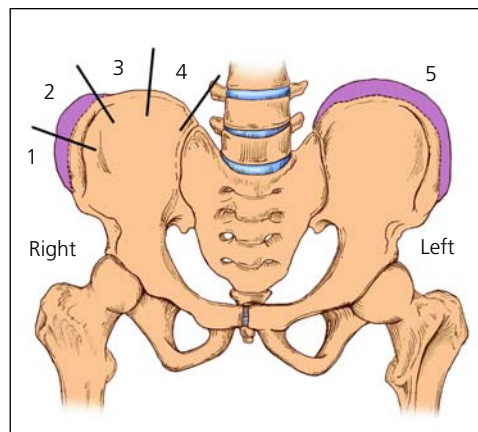


FIGURE 1. Ossification of the iliac apophysis starts at the anterior superior iliac spine and progresses posteromedially. The iliac crest is divided into quadrants, and the stage of maturity is designated as the number of ossified quadrants. For example, 50 percent ossified is a Risser grade 2. On the anatomic left (right side of the figure), all quadrants are ossified and the apophysis is fused to the iliac crest, for a Risser grade 5.

tion of the iliac apophysis, proceeding to grade 4, which signifies 100 percent ossification (*Figure 1*). A Risser grade of 5 means the iliac apophysis has fused to the iliac crest after 100 percent ossification. Children usually progress from a Risser grade 1 to a grade 5 over a two-year period. One study⁸ found that immature patients (Risser grades 0 and 1) with a spinal curvature measuring 20 to 29 degrees had a 68 percent probability of progression of 6 degrees or more during remaining growth. Patients closer to maturity (Risser grades 2 to 4) and with the same degree of scoliosis had a 23 percent probability of progression.⁸ Curves measuring 5 to 19 degrees in immature patients had a 22 percent probability of progression, while small curves in mature patients had only a 1.6 percent probability of progression.⁸

If other clinical markers of maturity such as Tanner staging or age at menarche are not consistent with the Risser grade, curve progression may proceed at a different rate. Thus,

The Author

K. ALLEN GREINER, M.D., M.P.H., is assistant professor of family medicine at the University of Kansas Medical Center, Kansas City, where he also received his medical degree and masters of public health degree. He completed a residency in family medicine and a fellowship in primary care at the University of Kansas Medical Center.

Address correspondence to K. Allen Greiner, M.D., M.P.H., Department of Family Medicine, University of Kansas Medical Center, 3901 Rainbow Blvd., Kansas City, KS 66160-7370 (e-mail: agreiner@kumc.edu). Reprints are not available from the author.

multiple measures of maturity are important to the clinical assessment of these patients.

Although a recent study¹⁴ showed an increased incidence of precocious puberty, the average female reaches a Tanner stage 1 at 11 years of age, the beginning of the growth spurt at 11.5 years of age, a Risser grade 1 at 12 years of age, and has an onset of menarche between 12 and 13 years of age. A female patient who matures consistent with these averages will have a relatively higher risk of curve progression before 12 years of age and a relatively lower risk of curve progression after 12.5 years of age.¹⁵

A scoliotic curve is more likely to progress in females, and thoracic curves or curves with a higher apex vertebral level are more likely to progress than other types of curves.^{8,14} Severe curves or moderate curves expected to progress beyond 100 degrees can lead to restrictive pulmonary disease and a possible reduction of life expectancy.¹¹ Curves of this magnitude usually have an infantile or juvenile onset rather than an adolescent onset.

Studies^{16,17} show an equal incidence of back pain and mortality in the general population and patients with adolescent idiopathic scoliosis. There are few recent studies¹⁸⁻²⁰ that evaluate the long-term cosmetic and psychosocial consequences of progressive spinal curves from the perspective of patients with scoliosis.

Clinical Presentation and Evaluation

Family physicians may need to examine children for scoliosis who have been referred from school-based screening programs. Because diastematomyelia (congenital splitting of the spinal cord), syringomyelia (cavity in the spinal cord), a tethered cord, or a spinal tumor can cause spinal curvature, physicians should ask the patient questions concerning neurologic symptoms. Neurofibromatosis can be associated with scoliosis, and a unilateral cavus foot can be a manifestation of intraspinal pathology.

Magnetic resonance imaging should be obtained in patients with an onset of scoliosis before eight years of age, rapid curve progression of more than 1 degree per month, an

Magnetic resonance imaging should be obtained in patients with an onset of scoliosis before eight years of age, rapid curve progression, an unusual curve pattern, neurologic deficit, or pain.

unusual curve pattern such as left thoracic curve, neurologic deficit, or pain. Spine abnormalities may present during routine examinations of 10- to 19-year-olds. Many examination techniques are used to evaluate patients presenting with spinal curvatures. Traditionally, the Adam's test with level plane and ruler or a scoliometer evaluation of the patient while bending forward was used to guide clinical decision-making.¹⁹ These measurements are difficult to standardize and should only be obtained when they will affect management decisions for an individual patient or to reassure the patient and family.⁶

Height measurements of the patient sitting and standing should be taken in the physician's office every three to four months. Documenting rapid height increases helps the physician determine the onset of the adolescent growth spurt and gauge the risk of rapid progression of the spinal curve. Sitting heights can be measured with the patient sitting in a standard chair and the height of the seat subtracted from the total height. Changes in sitting height can be less than changes in standing height and give a better estimate of truncal growth rate.

Any examination data must be combined with a thorough history to assess skeletal and sexual maturation.²¹

If an examination of the back is conducted, the physician should begin with a survey of the back while the patient is standing. Physicians may be misled by scapular or shoulder asymmetry and should focus on waist crease asymmetry or spine deviation during the upright examination. When measuring waist crease asymmetry, subtract perpendicular height from the iliac crests on each side. Radiographs should only be considered when a

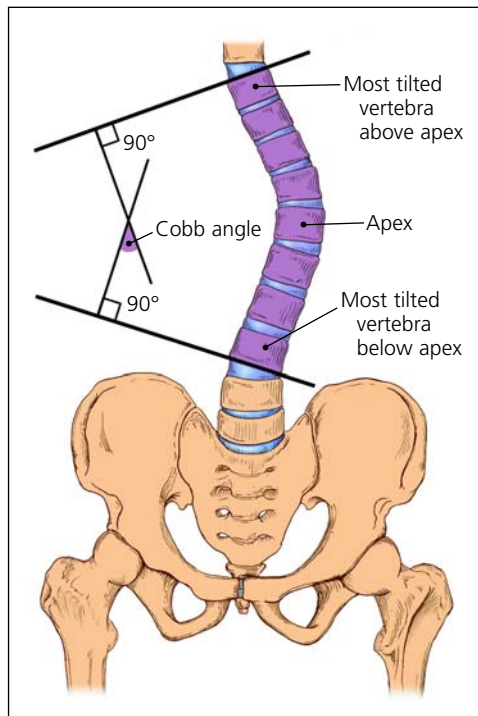


FIGURE 2. To use the Cobb method of measuring the degree of scoliosis, choose the most tilted vertebrae above and below the apex of the curve. The angle between intersecting lines drawn perpendicular to the top of the top vertebrae and the bottom of the bottom vertebrae is the Cobb angle.

patient has a curve that might require treatment or could progress to a stage requiring treatment (usually 40 to 100 degrees).²²

Radiologic Evaluation and Classification

The standard radiologic evaluation of adolescent idiopathic scoliosis consists of standing posteroanterior radiographs of the full spine. Follow-up is necessary in those patients with severe curves who are at risk for significant curve progression or require some form of treatment. Any discrepancy in leg length should be corrected with a block placed under the patient's shorter leg when radiographs are taken. One study²³ has shown that long-term management of scoliosis poses no radiograph-related risks to patients, but posteroanterior views assure maximal safety by minimizing radiation to the breasts. The Cobb method is used to measure the degree of scoliosis on the posteroanterior radiograph (Figure 2). In addition to curve degree, physicians should describe curves as "right" or "left," based on their curve convexity. Standard measurement error is 3 to 5 degrees for the same

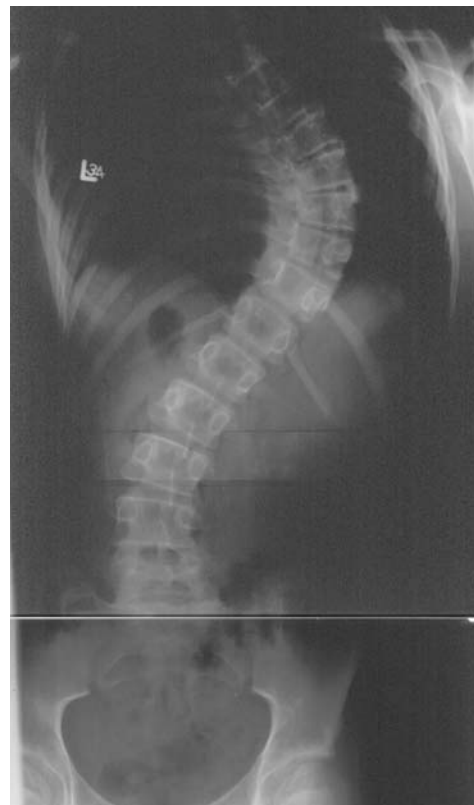

FIGURE 3. Posteroanterior radiograph of the spine in a patient with a thoracic spinal curve. Right thoracic curve, T6-11 (most tilted vertebrae above apex of curve T6, most tilted vertebrae below apex of curve T11). The degree of curvature is 65.

observer and 5 to 7 degrees for different observers when the same end vertebrae are used for measurements.^{24,25} Thus, physicians should use the same end vertebrae for subsequent measurements and assume that some measurement change may be caused by error rather than true curve progression.

Posteroanterior radiographs should be viewed in reverse to normal chest radiographs with the patient's right side on the physician's right side. Curves are named for the location of the apex vertebrae, and may be described as thoracic (Figure 3), lumbar, thoracolumbar, cervical, or double major (two curves in different spinal regions). A thoracolumbar curve (Figure 4) has an apex vertebrae at T12 or L1. Thoracic and lumbar curves have apex vertebrae in the middle of the thoracic and lumbar regions, respectively. A double curve (Figure 5) has a major and a minor curve (based on size and flexibility) and a primary and secondary curve (based on respective development). A compensatory curve is nonstructural and

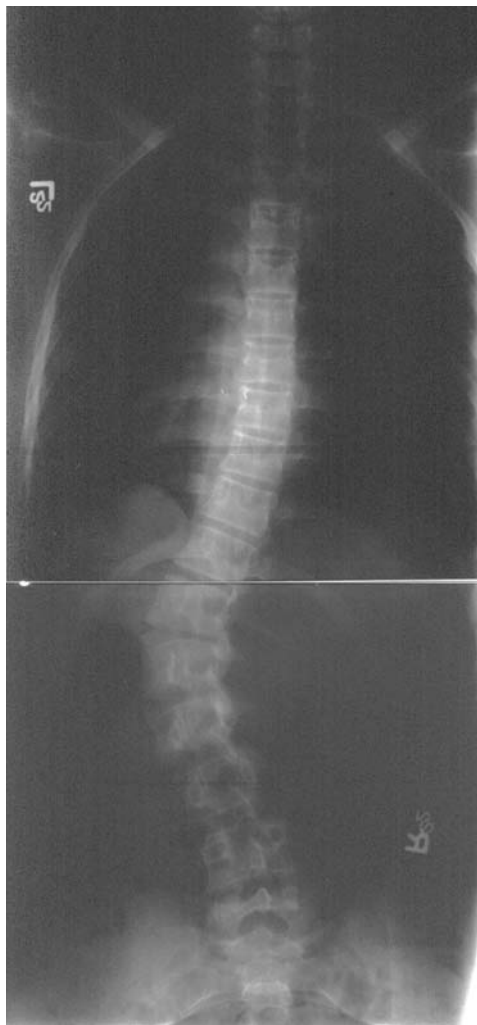

FIGURE 4. Posteroanterior radiograph of the spine in a patient with a thoracolumbar spinal curve. Left thoracolumbar curve, T10-L3 (most tilted vertebrae above apex of curve T10, most tilted vertebrae below apex of curve L3). The degree of curvature is 56.

develops to balance out a primary curve. A nonstructural curve differs from a structural curve because it can correct on lateral bending, distraction, or sitting.

Management and Follow-up

The primary goal of treating adolescent idiopathic scoliosis is preventing progression of the curve magnitude. Curves less than 10 to 15 degrees require no active treatment and can be monitored, unless the patient's bones are very immature and progression is likely. Moderate curves between 25 and 45 degrees in patients lacking skeletal maturity used to be treated with bracing, but this treatment has

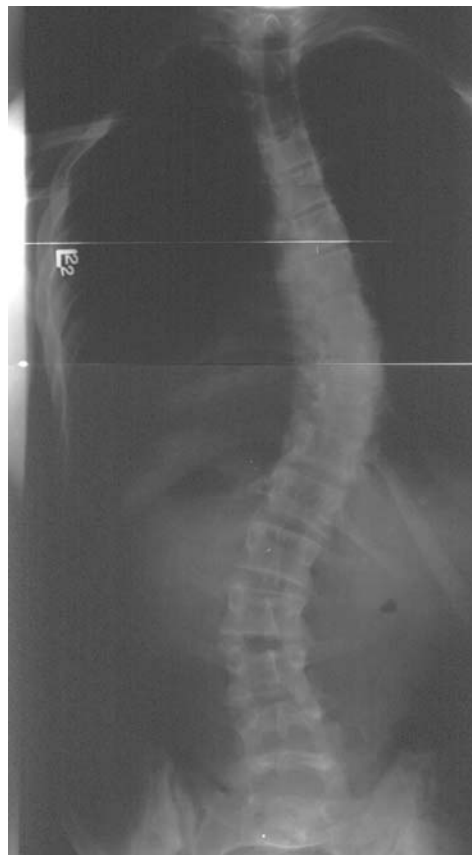

FIGURE 5. Posteroanterior radiograph of the spine in a patient with a double spinal curve. Double curve: right thoracic curve, T5-12 with a degree of curvature of 45; left lumbar curve, T12-L4 with a degree of curvature of 35.

never been proven to prevent curve progression. Poor compliance with wearing a brace obviates any potential usefulness of the therapy.²⁶ Much controversy surrounds brace indications, and trends over the past 20 years have moved toward no bracing or bracing only the more significant curves (20 to 50 degrees). Evidence²⁷⁻²⁹ showing the low symptomatic burden of patients with curves less than 60 degrees has influenced this trend away from treatment with bracing.

Most patients with adolescent idiopathic scoliosis who require treatment with a brace may use a thoracolumbar-sacral orthosis (TLSO) or a cervicothoracolumbar-sacral

Bracing and surgery are reserved for patients with severe scoliosis curves.

orthosis (CTLSO). Recommendations for optimal use of braces vary from eight to 24 hours a day depending on the style of brace chosen.

In patients with a curve severe enough to require surgery (greater than 45 degrees in adolescents and greater than 50 degrees in adults), rod placement and bone grafting may be necessary to achieve partial or complete correction. Patient preference is essential in deciding on a surgical treatment, and primary care physicians should work closely with patients and their families to reach optimal individual outcomes.

The author thanks Marc Asher, M.D., for editorial assistance, and Anne D. Walling, M.D., for review of the manuscript.

The author indicates that he does not have any conflicts of interest. Sources of funding: none reported.

REFERENCES

1. Yawn BP, Yawn RA, Hodge D, Kurland M, Shaughnessy WJ, Ilstrup D, et al. A population-based study of school scoliosis screening. *JAMA* 1999;282:1427-32.
2. Soucacos PN, Soucacos PK, Zacharis KC, Beris AE, Xenakis TA. School-screening for scoliosis: a prospective epidemiological study in northwestern and central Greece. *J Bone Joint Surg Am* 1997;79:1498-503.
3. Kane WJ. Scoliosis prevalence: a call for a statement of terms. *Clin Orthop* 1977;126:43-6.
4. Higginson G. Political considerations for changing medical screening programs. *JAMA* 1999;282:1472-4.
5. Morais T, Bernier M, Turcotte F. Age- and sex-specific prevalence of scoliosis and the value of school screening programs. *Am J Public Health* 1985;75:1377-80.
6. Grossman TW, Mazur JM, Cummings RJ. An evaluation of the Adams forward bend test and the scoliometer in a scoliosis school screening setting. *J Pediatr Orthop* 1995;15:535-8.
7. U.S. Preventive Services Task Force. Guide to clinical preventive services. 2d ed. Baltimore: Williams & Wilkins, 1996:517-29.
8. Lonstein JE, Carlson JM. The prediction of curve progression in untreated idiopathic scoliosis during growth. *J Bone Joint Surg Am* 1984;66:1061-71.
9. Carr AJ. Adolescent idiopathic scoliosis in identical twins. *J Bone Joint Surg Br* 1990;72:1077.
10. Miller NH. Cause and natural history of adolescent idiopathic scoliosis. *Orthop Clin North Am* 1999;30:343-52.
11. Weinstein SL, Ponseti IV. Curve progression in idiopathic scoliosis. *J Bone Joint Surg Am* 1983;65:447-55.
12. Weinstein SL, Zavala DC, Ponseti IV. Idiopathic scoliosis: long-term follow-up and prognosis in untreated patients. *J Bone Joint Surg Am* 1981;63:702-12.
13. Weinstein SL. Natural history. *Spine* 1999;24:2592-600.
14. Peterson LE, Nachemson AL. Prediction of progression of the curve in girls who have adolescent idiopathic scoliosis of moderate severity. Logistic regression analysis based on data from The Brace Study of the Scoliosis Research Society. *J Bone Joint Surg Am* 1995;77:823-7.
15. Nachemson A. A long term follow-up study of non-treated scoliosis. *Acta Orthop Scand* 1968;39:466-76.
16. Branthwaite MA. Cardiorespiratory consequences of unfused idiopathic scoliosis. *Br J Dis Chest* 1986;80:360-9.
17. Cordover AM, Betz RR, Clements DH, Bosacco SJ. Natural history of adolescent thoracolumbar and lumbar idiopathic scoliosis into adulthood. *J Spinal Disord* 1997;10:193-6.
18. Raso VJ, Lou E, Hill DL, Mahood JK, Moreau MJ, Durdle NG. Trunk distortion in adolescent idiopathic scoliosis. *J Pediatr Orthop* 1998;18:222-6.
19. Bengtsson G, Fallstrom K, Jansson B, Nachemson A. A psychological and psychiatric investigation of the adjustment of female scoliosis patients. *Acta Psychiatr Scand* 1974;50(1):50-9.
20. White SF, Asher MA, Lai SM, Burton DC. Patients' perceptions of overall function, pain, and appearance after primary posterior instrumentation and fusion for idiopathic scoliosis. *Spine* 1999;24:1693-700.
21. Amendt LE, Ause-Ellias KL, Eybers JL, Wadsworth CT, Nielsen DH, Weinstein SL. Validity and reliability testing of the Scoliometer. *Phys Ther* 1990;70:108-17.
22. Bunnell WP. Outcome of spinal screening. *Spine* 1993;18:1572-80.
23. Drummond D, Ranallo F, Lonstein J, Brooks HL, Cameron J. Radiation hazards in scoliosis management. *Spine* 1983;8:741-8.
24. Morrissy RT, Goldsmith GS, Hall EC, Kehl D, Cowie GH. Measurement of the Cobb angle on radiographs of patients who have scoliosis. Evaluation of intrinsic error. *J Bone Joint Surg Am* 1990;72:320-7.
25. Puijts JE, Hageman MA, Keessen W, van der Meer R, van Wieringen JC. Variation in Cobb angle measurements in scoliosis. *Skeletal Radiol* 1994;23:517-20.
26. DiRaimondo CV, Green NE. Brace-wear compliance in patients with adolescent idiopathic scoliosis. *J Pediatr Orthop* 1988;8:143-6.
27. Roach JW. Adolescent idiopathic scoliosis. *Orthop Clin North Am* 1999;30:353-65.
28. Karachalios T, Roidis N, Papagelopoulos PJ, Karachalios GG. The efficacy of school screening for scoliosis. *Orthopedics* 2000;23:386-91.
29. Dickson RA. Spinal deformity—adolescent idiopathic scoliosis. Nonoperative treatment. *Spine* 1999;24:2601-6.

Scoliosis Questions

1. The resident who has most recently participated in the orthopedics rotation should answer this question: What part of the skeleton is assessed during Risser Staging?
2. The resident who has most recently been on a ship, boat, or other waterborne craft should tell the group what percent of scoliosis is due to a secondary condition.
3. The residents with the 3 shortest last names should each name a unique cause of non-idiopathic (secondary) scoliosis, and 1 additional fact about that condition.
4. The youngest resident in the group should tell the group the relationship between gender and scoliosis.
5. The resident with the last name alphabetically in the group should tell the group the relationship between Risser Stage, Tanner Stage, and scoliosis progression.
6. The resident who was born furthest from your current location should tell the group at what Cobb Angles would respiratory compromise be expected with scoliosis.
7. The resident should tell the group the angle on the scoliometer that should prompt ordering of scoliosis films, and should do so in their best Southern drawl.

Scoliosis Board Review

1. A 14-year-old girl comes to your office because her mother is concerned about scoliosis. The mother had mild scoliosis as an adolescent, but she did not require treatment. The girl is previously healthy and participates in sports at school. She denies back pain, weakness, or abnormal sensations. On physical examination, lumbar asymmetry is apparent when she bends forward with her arms hanging down. There are no cutaneous findings, and her neurologic examination results are normal. You order posteroanterior and lateral radiographs of the spine to evaluate the degree of scoliosis.

Of the following, the radiographic finding that is MOST suggestive of a nonidiopathic cause for this girl's scoliosis is a

- A. Cobb angle of 30 degrees
- B. lack of thoracic kyphosis
- C. lumbar curve to the left
- D. thoracic curve to the right
- E. widening of the pedicles

2. While examining a newborn, you note a persistent curve in the spine regardless of the baby's position. You order spine radiographs, which reveal multiple vertebral malformations and segmentation defects.

Of the following, the MOST appropriate studies to guide further management are

- A. chromosome analysis and renal ultrasonography
- B. echocardiography and chromosome analysis
- C. echocardiography and renal ultrasonography
- D. head ultrasonography and ophthalmology consultation
- E. renal and head ultrasonography

3. You work as a voluntary attending pediatrician in the resident continuity clinic at your local hospital. You are precepting a resident, who tells you that she has just evaluated a 16-year-old varsity volleyball player. The girl's height is 71 inches, weight is 125 lb, and blood pressure is 115/74 mm Hg. The resident is concerned about scoliosis and a 3/6 holosystolic murmur heard at the cardiac apex with radiation to the left axilla

Of the following, the MOST likely diagnosis for this patient is

- A. Ehlers—Danlos syndrome
- B. infective endocarditis
- C. Marfan syndrome
- D. rheumatic heart disease
- E. Williams syndrome

4. A 7-year-old boy who is new to your practice comes in for evaluation of developmental delay and poor school performance. He began speaking in sentences at age 4. He repeated kindergarten and is struggling in first grade. On physical examination, you note that he has fair hair and light skin compared with his brown-haired, olive-skinned younger brother and mother. He is wearing thick glasses, and his mother says that he was diagnosed as being near-sighted when he was 2 years old. He has a lanky build with long fingers, and on forward bending, there is a curve in the thoracolumbar spine.

Of the following, the condition that is MOST consistent with this presentation is

- A. alkaptonuria
- B. homocystinuria
- C. nonketotic hyperglycinemia
- D. oculocutaneous tyrosinemia
- E. phenylketonuria

1 (E) 2 (C) 3 (C) 4 (B)