



NCC Pediatrics Continuity Clinic Curriculum: Adolescent III: Acne



Overall Goal:

Identify key adolescent health issues and become comfortable interviewing an adolescent.

Overall Outline:

Adolescent I:

Contraception

Adolescent II:

Menstrual Irregularities

Adolescent III:

Acne

Pre-Meeting Preparation:

- "Acne Vulgaris in the Pediatric Patient" (*PIR, 2019*)
- **What's in that product?** Select a common non-prescription acne product and determine what its active component(s) are and what its mechanism of action should be (*e.g. Proactiv, Stridex, Clearasil, Neutrogena skinID*).

Conference Agenda:

- Complete Adolescent III Quiz & Case Studies
- **What's in that product?** Share your findings with your continuity group.

Extra Credit:

- [Evidence-Based Recommendations for the Diagnosis and Treatment of Pediatric Acne](#) (*Pediatrics, 2013- Clinical Practice Guideline*)
- [Complementary, Holistic, and Integrative Medicine: Acne](#) (*PIR, 2013*)
- **iPLEDGE:** restricted-distribution program for **Accutane** for severe, recalcitrant nodular acne. If you think your patient is eligible, **place consult to see Adolescent or Derm.** If female, **place on OCPs**, as iPLEDGE requires 30 day window of "effective contraception".
- [Skin of Color Society](#)
- **"10 Tips for Clearing Acne in Skin of Color"** *American Academy of Dermatology Association*
- [American Acne & Rosacea Society-Pediatric Treatment Recs-](#) QUICK visual reference!

© Developed 2012 by MAJ Jennifer Hepps, MAJ Patricia Kapunan, Dr. Harshita Saxena, and COL Jeff Hutchinson. Edited 2018 by CPT Christopher Stark. Update C. Carr, 2021.

Acne Vulgaris in the Pediatric Patient

Rosalind Ashton, MD, MSc,* Miriam Weinstein, MD, FRCPC†

*King's College London School of Medical Education, St. John's Institute of Dermatology, London, United Kingdom

†The Hospital for Sick Children, Toronto, Ontario, Canada

Practice Gap

Acne vulgaris is a common disease seen in pediatric practices, and pediatricians should be able to develop management strategies using standard therapies, including retinoids.

Objectives After completing this article, readers should be able to:

1. Describe the pathophysiology of acne.
2. Outline treatment options based on a patient's clinical presentation.
3. Discuss mechanisms of action and adverse effects of common acne medications.
4. Explain treatment options for postacne sequelae.

AUTHOR DISCLOSURE Dr Ashton has disclosed no financial relationships relevant to this article. Dr Weinstein has disclosed funding from La Roche Posay through her hospital's charitable foundation for a program to teach patients with eczema and their families about the disease and how to manage it; is an advisory board leader/lecturer on eczema for Pfizer; is an advisory board member for Amgen and Pfizer on eczema; is an advisory board consultant for Sanofi Genzyme; is a consultant for Unilever; and is a consultant for Paladin Labs. This commentary does contain a discussion of an unapproved/investigative use of a commercial product/device.

ABBREVIATIONS

BPO	benzoyl peroxide
D+A/BPO	doxycycline + adapalene/ benzoyl peroxide
DRESS	drug reaction with eosinophilia and systemic symptoms
FDA	Food and Drug Administration
IBD	inflammatory bowel disease
PDL	pulsed dye laser
TLR	Toll-like receptor

INTRODUCTION

Acne vulgaris is a ubiquitous disease of the pilosebaceous unit, characterized by a long-term course with recurrences and relapses. It affects approximately 85% of adolescents and may persist until well into a patient's 20s and 30s. (1)(2)(3) Psychological sequelae can be substantial and should not be underestimated. This common, very visible skin condition presents at a time when appearance is acutely important and noticeable disease marring that appearance is distressing. Embarrassment contributes to lower self-esteem and feelings of unattractiveness and worthlessness, which may be present not only during active flare-ups but also with long-lasting postinflammatory hyperpigmentation and permanent scarring. (4)

The aim of this review is to offer up-to-date information on pathophysiology, evaluation, and management strategies for this common disease.

The treatment of acne conglobata, acne fulminans, cloracne, drug-induced acne, hidradenitis suppurativa, inflammatory disorders in which acne is a major feature, acne keloidalis nuchae, and dissecting cellulitis of the scalp is beyond the scope of this review but should be maintained in the differential diagnosis when clinically relevant.

TYPES OF ACNE

Although the bulk of this article focuses on acne in adolescence, mention of acne during earlier childhood is addressed first.

Neonatal Acne (Neonatal Cephalic Pustulosis)

Having its onset in the first 2 weeks of life and defined as presenting at less than 6 weeks of age, neonatal acne is characterized by papules and pustules usually on the face. It is believed that this eruption is **not a true acne** but rather an **inflammatory reaction to *Malassezia*** species such as *Malassezia furfur* (5) and *Malassezia sympodialis*, (6) and it is best referred to as *cephalic pustulosis*. However, there is **some controversy** about whether this acneiform eruption is related to *Malassezia* species. **Increased sebum production**, likely due to **circulating maternal androgens**, by active sebaceous glands during this period also contributes. This eruption **typically self-resolves** but may be treated with **topical 2% ketoconazole twice daily**, further supporting the argument for a relationship with *Malassezia*. Often a **mild topical corticosteroid** is added for its anti-inflammatory benefit.

Infantile Acne

The age ranges used to define the following categories refer to the age at onset of disease rather than the age at which the patient presents to a health-care provider. **Acne occurring between 6 weeks and 1 year of age defines infantile acne.** It is more common in **males**, typically presenting as **inflammatory papules on the cheeks**, although true comedones can be present. This **may last for 6 to 12 months or for several years.** (7) It is considered **more difficult and important to treat** because **scarring is significantly more likely to occur.** Most cases of infantile acne resolve by age 4 years, but there is **weak evidence** that it is a **predictor of more severe acne as an adolescent.** (8) Patients, especially older infants, with other signs of hormonal abnormalities (eg, **virilization**) warrant evaluation and referral to a pediatric endocrinologist because this **may be** the first sign of a **treatable endocrinopathy.** **Treatments**, although all off-label, are the **ones used for adolescent acne**, including oral therapy where necessary.

Mid-childhood Acne

Defined as **presenting between 1 and 7 years** of age, mid-childhood acne is **very rare** and should raise suspicion for an **endocrinopathy.** Appropriate evaluation includes looking for causes of hyperandrogenism, including **Cushing disease, virilizing tumors, and congenital adrenal hyperplasia.** History and physical examination, family history, **analysis of height and weight charts, and serologic testing for total and free testosterone, dehydroepiandrosterone, 17-hydroxyprogesterone, and luteinizing hormone/follicle-stimulating hormone** should be performed. (9) **Treatment** should address the underlying cause of acne, which should

be managed concurrently by a pediatric endocrinologist. The dermatologic options are much the **same as for adolescent acne.**

Preadolescent Acne

Acne occurring **between 7 and 11 years** of age is less common and **may require** evaluation and possible referral to a pediatric **endocrinologist.** (10) Although acne in this age group is usually due to **isolated premature adrenarche**, it may be the first presenting sign in a child with **true precocious puberty, congenital adrenal hyperplasia, polycystic ovarian syndrome, or a rare virilizing tumor.** **Adenoma sebaceum (facial angiofibromas)**, a key feature of tuberous sclerosis, usually appears before age 10 years and can mimic facial acne. (11) **Acne caused by an endocrinopathy will always have other presenting signs on physical examination, including body odor, advanced height and weight, breast development, and axillary and pubic hair.** A thorough history and physical examination should be performed when a patient presents with acne in this age group. Treatment, in addition to addressing the underlying cause, is largely the same as for adolescent acne (except for tetracycline antibiotics).

PATHOPHYSIOLOGY

The hallmark of acne is **microcomedones**, which **evolve into** the **noninflammatory** lesions of **open and closed comedones** (colloquially known as *blackheads* and *whiteheads*). Comedones are usually the first lesions to occur. **Inflammatory lesions manifest as papules and pustules, occasionally** developing into **nodules**, a sign of severe disease. All lesions may be present in combination and in varying stages of healing or development. **Scarring** has many **descriptive morphologies: atrophic, icepick, boxcar, and rolling.** (12) **Keloid** scarring may also occur. **Distribution** predominantly affects areas where there is an **increased density of pilosebaceous units**, such as the face (usually first appearing along the “T-zone” distribution of the brow, glabella, and bridge of the nose), chest, shoulders, and back. Development of acne is **correlated with onset of adrenarche** rather than with chronologic age.

A tetrad of **inflammation, abnormal shedding of keratinocytes, increased production of sebum**, and association with *Propionibacterium acnes* contributes to the pathogenesis of acne. (13)

Increased production of sebum by the sebaceous glands is associated with increased androgenic activity by the adrenals and gonads, occurring during puberty. A

sebum-rich environment alters desquamation, contributes to follicular plugging, and encourages growth of *P. acnes*. (13)

P. acnes, a gram-positive bacillus, contributes to acne lesions by accumulating in a plugged follicle and releasing extracellular debris, of which many components are immunogenic and promote inflammation, including heat shock proteins, porphyrin, protease, and squalene peroxides. (13) This release not only attracts immune cells such as neutrophils, monocytes, and lymphocytes, causing a local inflammatory response, but also contributes to a cascade of proinflammatory events inside the distended follicle, ultimately causing rupture and spilling of bacterial contents and cytokines into the dermis. This results in papules, pustules, and nodules. *P. acnes* is also able to create a biofilm, a process that bacteria use to become more adherent to a surface. (14) This biofilm is more prevalent in individuals with acne, and it may act as a barrier to antibiotic penetration. (15)

Toll-like receptors (TLRs) are part of the innate immune system and are responsible for recruiting pro-inflammatory cells when threatened by pathogens. There is a positive correlation between the severity of acne lesions and the concentration of cells expressing TLR-2. *P. acnes* binds to TLR-2, promoting inflammatory cells to make their way into the pilosebaceous unit to lyse the bacterial invader. It is not surprising, then, that combination therapies such as benzoyl peroxide (BPO), which is bactericidal against *P. acnes*, and a topical retinoid, which helps downregulate TLR-2, thereby decreasing inflammation, have been shown to be efficacious. (16)

Acne treatments are, therefore, focused on targeting 1 or more components of this pathophysiologic tetrad.

ACNE AND HYGIENE

Facial cleansing is a common part of many patients' skin care routine and acne management. Data are lacking to strongly support the role of cleansing as an important therapeutic intervention. However, cleansing is reasonable and may remove excess sebum and debris, which many patients prefer. It is important to counsel patients that washing does not need to be done multiple times a day; overzealous washing with harsh or abrasive products may irritate skin or strip it of its moisture, disturbing the barrier function of the stratum corneum and encouraging more sebum production. (17)(18) Explaining that acne is not infectious or a result of lack of cleanliness may also be useful when explaining the roles of gentle cleansing and application of medication.

ACNE AND DIET

We know that the Western diet (often described as a high glycemic index diet) upregulates insulin/insulinlike growth factor 1. (19) This point, compounded with the fact that there is already an upregulation of insulinlike growth factor 1 during puberty, exaggerates sebaceous gland cell proliferation and contributes to increased sebum production in this already upregulated time of development. (20) Randomized prospective trials on this topic are lacking, although a small older randomized trial that looked at 43 male patients with acne noticed improvement in their skin as well as BMI after a 12-week low glycemic index diet. (21)

In 2016, LaRosa et al (22) conducted a case-control study looking at 225 adolescents with moderate acne (as reported by a dermatologist using the Global Acne Assessment Scale) and those without acne. Using self-reported diet interviews, the authors found that total dairy consumption was slightly higher in the acne group than in the control group, reaching significance, with an association especially between acne and skim milk consumption. (22) Full-fat milk was not associated with higher rates of acne in this study, but the opposite was found in 2,489 high school students, especially in male participants, in a 2017 Norwegian questionnaire-based study. (23) Both sets of authors acknowledged the need for prospective studies showing the impact of dairy elimination in diet before making specific dietary recommendations for patients with acne. We, therefore, recommend a balanced diet as supported by the American Food Guide. (24)

EVALUATION

Several acne severity grading scales exist, including the Global Acne Grading System (Table 1), the Global Acne Assessment Scale, the Leeds scale, and the newly described patient-centered acne severity scale. (25)(26)(27)(28) The first 3 are validated. We encourage the serial grading of lesions using a single consistent scale and the Dermatology Life Quality Index before and during treatment. Consistent use helps to survey the evolution of improvement or to decide whether the clinician needs a new strategy. One should consider clinical photography.

Broadly, mild acne is described as limited disease consisting of noninflammatory comedones and/or minimal inflammatory lesions. Moderate acne usually has more lesions and may have a greater spread. Severe acne usually denotes acne with high risk of scarring and/or scarring and, possibly, nodules (Figs 1-3). (29)(30)

TABLE 1. Global Acne Grading System

LOCATION	FACTOR × GRADE (0-4) = LOCAL SCORE
Forehead	2
Right cheek	2
Left cheek	2
Nose	1
Chin	1
Chest and upper back	3

Global score = summation of local scores: 0, none; 1-18, mild; 19-30, moderate; 31-38, severe; ≥39, very severe. Grades: 0, no lesions; 1, ≥1 comedone; 2, ≥1 papule; 3, ≥1 pustule; 4, ≥1 nodule. Adapted with permission from Doshi A, Zaheer A, Stiller MJ. A comparison of current acne grading systems and proposal of a novel system. *Int J Dermatol.* 1997;36(6):416-418. © 1997 Blackwell Science Ltd.

MANAGEMENT

Choosing therapy for acne vulgaris can be overwhelming because there are many options and products available both over the counter and by prescription. There is **no single best therapy for acne management** because **many factors need to be considered** in selecting therapy. Often trials of different products may be needed to establish the most effective and best-tolerated therapies.

There is not necessarily a common starting point for all patients with the same presentation of acne. Selection of a treatment plan needs to include **factors** such as the **mechanism** of action of medication, the **extent of acne**, the **morphology** of acne, **tolerance of medications**, **compliance**

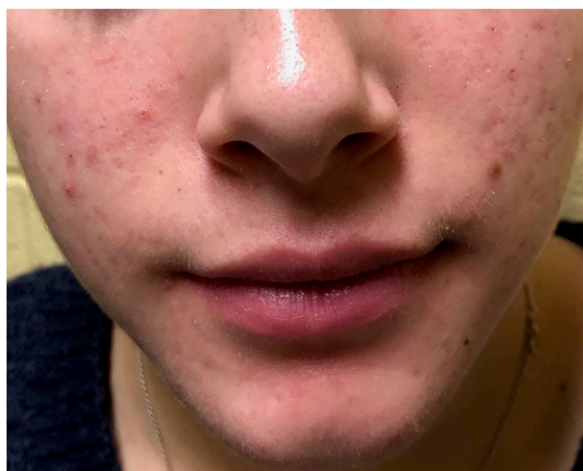

Figure 1. Moderate, mixed inflammatory and comedonal acne.

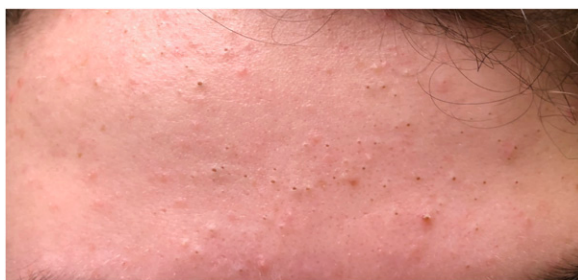

Figure 2. Moderate to severe comedonal acne.

with treatment regimens, **cost**, and **patient preference**. The Management section highlights the types and roles of medications, and Table 2 helps the clinician consider which treatments to select for given clinical situations. For example, a patient with mild comedonal acne and oily skin may do well starting with a medium-strength topical retinoid, whereas a patient with similar acne but severe dryness from atopic dermatitis may need to use a very mild retinoid every other night or even try a BPO, which is mostly an anti-inflammatory medication but can have some mild comedolytic activity.

Management should begin with an explanation of acne and management of expectations. Patients and their families should understand that acne is best thought of as a **chronic disease of adolescence** and that the **goal is control, not cure**. Therapy should be tailored to the patient and **include consideration of the severity and extent of disease**, **concomitant skin disease** such as atopic dermatitis, **propensity for scarring**, **patient reliability/motivation**, **cost**, **tolerability of therapy**, and degree of **health literacy** of the patient and the family. A trial of therapy must be given an **appropriate amount of time** to exert its effects, and patients must be counseled on adverse effects and what to expect to ensure maximum satisfaction and compliance.

In addition to topical and systemic therapies, patients should be **counseled on avoidance of comedogenic cosmetics and moisturizers and mechanical friction**. Picking at lesions risks scarring and may be a manifestation of an underlying psychiatric condition, especially in young girls,

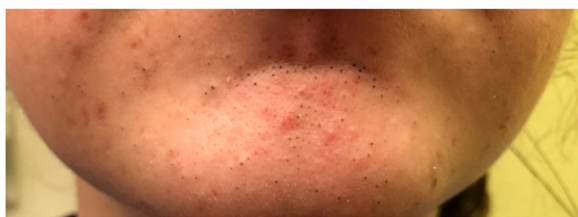


Figure 3. Severe comedonal acne.

TABLE 2. Suggested Management Approaches for Select Clinical Situations

CLINICAL/PATIENT FEATURE	MANAGEMENT STRATEGIES TO CONSIDER
Morphology	
Mostly comedonal	Topical retinoid ± BPO
Mostly inflammatory	Topical antibiotic with BPO or BPO alone
Mixed comedonal/inflammatory	Systemic treatment (oral antibiotic and/or OCP)
	Topical therapy + (oral antibiotic and/or OCP)
	Topical retinoid + topical BPO ± topical or oral antibiotic ± OCP
Severity	
Mild	Topical therapy
Moderate	Topical therapy and/or systemic treatment (oral antibiotic and/or OCP)
Severe	Consider isotretinoin
Extent	
Face	Topical therapy (if not severe); consider fixed-dose combination topical and/or oral therapy
Chest	Topical and/or systemic treatment (oral antibiotic and/or OCP)
Back	If widespread consider oral therapy
Compliance	
Good	Multiple medications applied at separate times may be appropriate
Limited	Consider fixed-dose combination therapy
Expense of medications	
Affordable/covered	Combined/fixed-dose combination products
Unaffordable/noncovered	Products used separately may be less costly but effective
History of eczema or sensitive skin	
Present	May need milder retinoid or less frequent application
Absent	Usually tolerate topical products

BPO=benzoyl peroxide, OCP=oral contraceptive pill.

a compulsive syndrome known as **acne excoriée**, which can be a component of body dysmorphic disorder. (31) Encouraging **sun protection** especially when selecting medication with photosensitivity adverse effects is also important.

Mild to Moderate Acne

Topical therapies are recommended as **first-line** treatment of **mild to moderate** acne and are also useful adjuncts when hormone therapy or oral antibiotics are used for moderate acne. Topical therapy includes **BPO, topical antibiotics, topical retinoids, and topically applied acids**. Retinoids are usually included in the regimen when comedones are present and can play a role in maintenance/prevention

as well once control is established. Often but not always, **moderate acne may require oral therapy** with **antibiotics** or **hormone** therapy. Adding topical BPO to reduce bacterial resistance and/or a topical retinoid to help with comedones is often warranted.

Severe Acne

Severe nodulocystic disease is an indication for **isotretinoin**, although other strategies can be used for severe acne and for patients who are unable or unwilling to use isotretinoin for severe acne.

A well-designed randomized, placebo-controlled trial from 2016 looked at **combination adapalene 0.3% and BPO 2.5% gel** and demonstrated **efficacy in moderate to**

This product's brand name is "Epiduo"

severe nonnodulocystic acne with good tolerability. This is the first study of a topical therapy showing excellent results against moderate to severe nonnodulocystic acne with good tolerability and should be considered for patients who refuse isotretinoin therapy. (32)

Oral doxycycline has also been studied in combination with adapalene 0.1% and BPO 2.5% (D+A/BPO) against isotretinoin for severe nodular acne. A 2014 randomized controlled trial concluded that D+A/BPO showed a favorable efficacy and safety profile compared with isotretinoin. D+A/BPO also seemed to reduce inflammatory lesions more rapidly by the second week of treatment. Although isotretinoin demonstrated superior total results after 20 weeks, this combination is an alternative for patients who are unwilling or unable to take isotretinoin and can be offered as an option for treatment of severe nodular acne. (33)

Acids

Salicylic Acid. Salicylic acid, a β -hydroxy acid, is an ingredient in many over-the-counter acne products, including cleansers. It exerts a desquamative effect on the skin, causing keratinocyte discohension in congested follicles by dissolving lipid bonds, thereby preventing comedones and improving the appearance of current ones. (34)(35) Its exfoliating abilities have made it a popular peeling agent in 20% or greater concentrations for active acne as well as postacne scarring.

Azelaic Acid. Azelaic acid, a naturally occurring dicarboxylic acid, is bactericidal against *P. acnes*, is anti-inflammatory, and reduces the proliferation of keratinocytes, thereby decreasing comedone formation. (36) This is a popular product in darker-skinned individuals because it may help to lighten post-inflammatory hyperpigmentation of old lesions via its antiproliferative effects on abnormally proliferating melanocytes and antityrosinase activity. (37) It is available in a 20% cream and a 15% gel and is typically applied twice daily. Adverse effects include mild to moderate irritation at the application site, which usually subsides after 2 to 4 weeks of continued use.

Glycolic Acid. Glycolic acid, an α -hydroxy acid, promotes exfoliation and desquamation of keratinocytes in the corneal layer. It is a widely used superficial and medium peeling agent used in cosmetic practices with evidence of improvement of acne scars. (38)

Anti-Inflammatory

Benzoyl Peroxide. BPO is a common active ingredient in many over-the-counter facial cleansers and anti-acne creams and gels. It is bactericidal against *P. acnes*, lysing

the cell wall by release of oxygen free radicals, and has comedolytic properties possibly by decreasing accumulation of free fatty acids, thereby enhancing follicular desquamation and decreasing follicular plugging. It has a fast onset of action and should be considered for initial treatment of mild to moderate disease. (39) Because the effect of BPO on *P. acnes* is a direct toxic effect rather than antibiotic, resistance has never been reported.

BPO is an excellent medication for patients with mild comedonal or inflammatory acne, a finding supported by several trials. (40)(41) BPO is available both with and without a prescription in concentrations ranging from 2.5% to 10%. Products sold over the counter include soaps, creams, washes, lotions, and gels. The prescription form generally involves a gel vehicle for enhanced efficacy or combines the BPO with another topical agent, such as an antibiotic or a retinoid, for enhanced ease of use and improved patient compliance. BPO, in 2.5% and 5% gels, was superior to vehicle for comedonal acne in several studies. (42)(43) For most patients, a single daily application of 5% is sufficient.

In addition to stinging, peeling, and burning sensations, which can be mitigated with noncomedogenic moisturizers and decreased frequency or nighttime use, patients should be warned that this product may bleach towels, bedding, and clothing. Rarely, BPO can cause an allergic contact dermatitis presenting with significant erythema, pruritus, and swelling. In such patients, BPO-containing products should be avoided. (44)

BPO has also been used in combination with a variety of other products conveniently available in the same vehicle. In a 2015 study by Kawashima et al (45) of 1.2% clindamycin and 3.0% BPO, 800 Japanese patients were randomized to receive clindamycin alone twice daily, clindamycin and BPO once daily, or clindamycin and BPO twice daily. Both combination products outperformed clindamycin on its own, with earlier onset of action and an acceptable tolerability profile in this population. (45)

Topical Antibiotics

Most topical antibiotic regimens use either clindamycin or erythromycin. As cited previously herein, topical antibiotic products are usually combined with BPO or a retinoid product.

Two well-designed double-blind, split-face studies compared tolerability of adapalene 0.3%/BPO 2.5% gel against clindamycin/BPO 3.75% gel in patients with moderate to severe acne. Despite having the lower concentration of BPO, the combination with the retinoid was associated with more burning and stinging. (46) The timing end

point was 21 days, and we do not know whether patients might adapt and experience less irritation if given a longer time frame.

In the interest of antibiotic stewardship, **prolonged antibiotic (topical or oral) monotherapy should be avoided whenever possible.** Adding BPO to a regimen that includes antibiotics will not only be an **additive** acne treatment but will also **reduce the risk of bacterial resistance.** (47)(48)

Dapsone is the newest of the **topical antibiotics** and is a **sulphonamide** drug that exerts its antibiotic effects by **inhibiting bacterial synthesis of folic acid.** It also exhibits **anti-inflammatory effects** by targeting the neutrophil and thereby decreasing inflammation. It is available in **5% to 7.5% gel formulations for patients older than 12 years.** A large double-blind, vehicle-controlled trial that included 2,238 patients 12 years and older with moderate acne as measured by a dermatologist was conducted using a validated scale. Patients were randomized to receive topical 7.5% dapsone gel or vehicle over a 12-week period, (49) and improvement was measured by looking at both inflammatory and noninflammatory lesion counts. Efficacy and tolerability were both acceptable using the **once-daily 7.5% gel,** with most patients reporting no to mild symptoms of drying. Once-daily dosing is an alternative to the **twice-daily dosing of the 5% dapsone gel.**

Patients should be warned about **peeling and erythema** at the application sites. The drug is **safe to use in** patients with **glucose-6-phosphate dehydrogenase deficiency.** (50)

Topical Retinoids

Derived from vitamin A, retinoids are a family of synthetic compounds that **play a role in cell differentiation and growth.** Retinoids bind to **specific retinoid receptors** in the **nuclei of keratinocytes;** of most interest are the retinoic acid receptors and retinoid X receptors. These medications are extremely effective at **normalizing the exfoliation of the epithelial lining of the follicle and are also comedolytic.** Improved exfoliation discourages follicular plugging, thereby **preventing the formation of microcomedones** (thus decreasing future true comedones and inflammatory lesions) and also promote the clearance of existing lesions. (51) In addition, retinoids help **create an aerobic environment, which is noxious to *P acnes*, and block** several important pro-inflammatory pathways known to contribute to acne, such as the **TLR and activator protein 1 pathways.** (52)

Tretinoin is a first-generation retinoid. It is extremely **photolabile and recommended for nighttime use.** Tazarotene and **adapalene,** classified as **third-generation** retinoids, are **more receptor selective.** Adapalene, available in

0.1% and 0.3% formulations, specifically binds to retinoic acid receptor α . It is the **most light stable** of the topical retinoids and is the **least susceptible to oxidation by BPO,** justifying its role in popular combination therapies.

Topical retinoids are used once daily to the affected area as a field treatment (**applying the product to** a more extensive **high-risk zone** as part of **preventive therapy rather than only treating individual lesions**). Retinoids are encouraged for use at night to minimize photodestruction, and patients are counseled that it **may take several weeks before they start to see improvement in their complexion.** Patients should also be aware that during the first month of therapy there may be a **paradoxical worsening** of their acne as the **drug encourages loosening of deeper comedones, which then come to the surface.**

Adverse effects of retinoids include peeling and irritation, and **many patients must start with low concentrations of the medicine or less frequent applications, working their way up to higher concentrations or more frequent applications.** Daytime moisturizers and sunscreen are important adjuncts. All vitamin A derivatives are designated as category C or X, and all women of childbearing potential should be made aware of this with **appropriate contraceptive counseling.** Patients **with atopic dermatitis** may require milder or **less frequent retinoids** (eg, every second or third night instead of nightly) because their skin tends to be more easily irritated. Patients are often advised to **avoid waxing, laser therapy, electrolysis, and exfoliation** at treated sites because the retinoids, in part, can reduce the protective stratum corneum layer, thus increasing risk of damage from such agents.

Combination Treatment

Combination products, in which more than 1 medication exists in a single vehicle, have the advantage of using multimodal therapy with **greater efficiency** and, therefore, **improved compliance.** (53) These are popular products and incorporate medications that address different etiologic factors of acne and can be used in mild-moderate disease and as adjuncts to systemic treatment for more severe cases. Combinations include **BPO with a topical antibiotic** (such as erythromycin or clindamycin) or a retinoid, **or an antibiotic with a retinoid;** evidence of effectiveness is mentioned previously herein. These products are often more costly than single-medication products but are also more convenient. They are **appropriate** as **first-line therapy** options for **all severities of acne** and are recommended in the latest comprehensive review on the management of acne in the *Journal of the American Academy of Dermatology.* (54)

Systemic Treatment Options

Antibiotics. Used for their anti-inflammatory as well as their *P. acnes* antimicrobial abilities, antibiotics are useful treatments in the armamentarium against acne, thereby targeting 2 of the 4 main causes.

The tetracyclines inhibit bacterial protein synthesis, leading to a bacteriostatic mechanism of action. They are the most commonly used antibiotics for the treatment of acne, although dental staining in children younger than 9 years precludes their use in this age group, and they should not be given to pregnant or breastfeeding women. The tetracyclines generally should not be taken with food, except doxycycline to protect against esophagitis. The most common adverse effects are photosensitivity, gastrointestinal upset, and, rarely, pseudotumor cerebri.

Doxycycline is commonly used in 2 doses: 50 to 100 mg daily or twice daily, and 40 mg daily as an extended-release therapy (which was originally introduced to mitigate its gastrointestinal symptoms). Although it is subantimicrobial, low-dose doxycycline was hypothesized to be helpful in the treatment of acne after its success in rosacea treatment. A 2015 randomized controlled trial (which included children 12 years and older; average age, 19 years) was designed to test the efficacy of doxycycline 40 mg once daily, doxycycline 100 mg once daily, and placebo for moderate to severe acne. A total of 662 patients were randomized in a 1:1:1 manner for 16 weeks. Both dosages were superior to placebo regarding inflammatory lesion count, and both dosages were comparable in the improvement of total number of lesions and reduction of inflammatory lesions. Adverse effects (most commonly headache, nausea, and vomiting) were reported more often in the 100-mg group. The authors concluded that the 40-mg extended-release dosage of doxycycline is an effective and safe option for those with inflammatory acne lesions. (55)

Minocycline is used to treat a variety of dermatologic problems, including acne vulgaris, perioral dermatitis, and rosacea. It is the most lipophilic of the tetracyclines, achieving significant levels in the pilosebaceous unit and reaching high concentrations in the skin and nails. For acne, it is typically prescribed as 50 to 100 mg once daily for approximately 12 weeks or as an extended-release formula. (56) Major adverse effects of minocycline include nausea, vomiting, and dizziness; phototoxicity; blue-black pigmentation of the skin, nails, teeth, bones, and mucous membranes (57); a minocycline-induced lupuslike reaction (58); and drug reaction with eosinophilia and systemic symptoms (DRESS). (59) It is for these reasons that the authors of the latest Canadian clinical practice guidelines

for acne in 2015 prefer tetracycline or doxycycline for the treatment of extensive moderate papulopustular acne. (60) Minocycline crosses the blood-brain barrier and should not be used in combination with isotretinoin owing to the risk of pseudotumor cerebri. Death is reported once in the literature (61) and twice in online articles found through common search engines. (62)(63) Minocycline hypersensitivity syndrome usually occurs within the first 6 to 8 weeks of therapy, beginning with flu-like malaise and a morbilliform rash. End organ failure most commonly involves the liver but can manifest itself as kidney failure, myocarditis, thyroiditis, cerebritis, or pneumonitis. The latest Cochrane review, published in 2012, looked at minocycline's efficacy and safety and concluded that it did not outperform other tetracycline antibiotics as once believed. It may also have more safety concerns than the other tetracyclines, (64) although it is now less expensive.

Treating acne with oral antibiotics alone should be avoided so as to prevent antibiotic resistance.

Hormone Treatment Options. Several controlled trials have reported the positive effect of oral contraceptive pills on acne, (65)(66) and postmenarchal female patients with acne may benefit from hormonal treatment of their acne with the aim of reducing the stimulation of the sebaceous glands and thereby decreasing sebum production. This treatment is especially helpful when presented with the patient with older-onset acne (>25 years old), which is located primarily on the lower face and jawline, or who complain of menstrual flare. (67) Hormone therapies are divided into 2 categories: androgen synthesis inhibitors (in which estrogen and progesterone combination oral contraceptive pills are included) and androgen receptor antagonists (which include spironolactone, flutamide, and cyproterone acetate). The latter are particularly useful if acne is the result of an endocrinologic abnormality such as polycystic ovarian syndrome.

Treatment typically requires 3 to 6 months until improvement is seen, and patients should be warned that acne can return after treatment cessation. Contraindications to this treatment include patients older than 35 years, those who are active smokers, and patients with a history of venous thromboembolism or hypercoagulability.

Isotretinoin. Isotretinoin (13-cis-retinoic acid), an oral retinoid, is indicated for the treatment of nodulocystic acne and is the most effective treatment for severe and recalcitrant disease. (68) It is the only medication that affects all components of the acne tetrad and the only medication with curative potential, although disease recurrence after cessation is possible. Isotretinoin does not bind to retinoid receptors but rather is metabolized to tretinoin,

which then binds to retinoic acid receptors. Tretinoin is extremely effective at decreasing sebum production by inducing apoptosis of the sebocytes, (69) and there is evidence that it also alters the bacterial environment of *P. acnes*. (70)

Medication dosing has been found to be most effective with daily doses of 0.5 to 1.0 mg/kg per day or a total cumulative dose of 120 to 150 mg/kg over the treatment duration (usually approaching 20 weeks). Newer, off-label trends include using lower-dose therapy often well below the standard dose. (71)(72) Although isotretinoin is usually reserved for severe and recalcitrant disease, there have been studies looking at this “low-dose” and also “intermittent” regimen in moderate acne over the past 10 years with some evidence to support both efficacy and fewer adverse effects.

All patients will experience some sort of generalized skin and mucous membrane dryness while receiving isotretinoin. Cholesterol and liver enzyme abnormalities may occur but are typically transient, although they should be monitored. (73) Baseline laboratory tests are recommended monthly for 3 months and then every 3 months thereafter, although screening for pregnancy in females should be monthly. Muscle aches, decreased night vision, and photosensitivity are also reported. Again, this drug should never be used in combination with a tetracycline antibiotic. There may be a connection to depressed mood, but a causal linkage of this medication to suicidal ideation and major depressive disorder has not been definitively proved, (74) and, perhaps unsurprisingly, several studies have demonstrated an improvement in patient quality of life and depression scales as their acne improves. (75)(76) Patient mood should be documented, and those with depressive symptoms should be assessed for suitability of isotretinoin and monitored or managed accordingly. This may include the need to involve mental health professionals. In addition, some believe that there is an increased risk of developing inflammatory bowel disease (IBD), especially ulcerative colitis, in those using isotretinoin. This is supported by some literature but not others. A large 2010 case-control study by Crockett et al (77) looked at more than 8,000 patients with IBD and assessed isotretinoin exposure. They found a positive correlation with the development of IBD and exposure especially at higher doses and longer durations. (77) Countering this hypothesis is a large population-based study that looked at 2,008 patients with IBD. The authors were unable to prove that a diagnosis of IBD followed a course of isotretinoin, although they emphasized that we do not fully know the impact of isotretinoin on the gut. (78) A 2016

meta-analysis of controlled studies concluded that isotretinoin was not associated with an increased risk of ulcerative colitis or Crohn disease, (79) but debate remains, especially when looking at confounding variables such as severity of acne and past acne treatments, such as using antibiotics. As of now, there is no clear evidence of a causal link between isotretinoin therapy and IBD.

Being derived from vitamin A, isotretinoin is teratogenic, and rigorous counseling regarding pregnancy prevention is mandatory for female patients. Two simultaneous forms of birth control are recommended at the time of writing the prescription, and pregnancy tests should be performed monthly. American practitioners are also required to enroll female patients in the iPLEDGE program (a mandatory distribution program in the United States for isotretinoin). (80)

Historically, patients treated with isotretinoin were counseled to avoid dermabrasion and other resurfacing techniques until 6 to 12 months after completion of therapy because of the perceived risk of difficulty healing or keloid scarring. An excellent 2017 review in *JAMA Dermatology* looked critically at procedures during isotretinoin therapy (81) and suggested that this notion is too cautious. A panel of American experts studied publications reporting 1,485 procedures and concluded that there was insufficient evidence to support delaying many procedures during the 6- to 12-month abstinence recommendation. Based on the available literature, only caution against mechanical dermabrasion and ablative laser use was recommended. We must emphasize that further work is needed in this area, and we suspect that there will be more prospective trials regarding procedures and isotretinoin therapy in the future.

Physical Treatment

Comedo Extraction. Using a specialized comedo extraction device, the dermatologist can physically remove debris from comedones, improving the appearance of a patient's acne and enhancing topical treatment penetration. This procedure is especially beneficial for deep or persistent comedones but should not be performed on inflamed lesions. Closed comedones may also be nicked with a sterile blade to ease expression of their contents. These procedures can produce bruising and potentially scars.

Intralesional Corticosteroid Injection. An injected high concentration of corticosteroid into a nodulocystic lesion can ameliorate its appearance within 48 to 72 hours. (82) A corticosteroid, usually triamcinolone 10 mg/mL, is injected directly into a nodule with the aim of flattening the lesion and decreasing surrounding inflammation.

Adverse effects, as with any corticosteroid, include **atrophy, telangiectasia, striae, and pigmentary changes**. It should not be offered as a treatment for widespread nodulocystic acne, and there are reports of systemic absorption of the drug. (83)

Cryotherapy. Occasionally cryotherapy has been used in the treatment of acne, but current supportive literature is lacking.

MAINTENANCE

Acne is a chronic disease, and many individuals experience lesions well into adulthood. (2) Each treatment should be trialed for 2 or 3 months and then advanced or tapered depending on clinical response. (62) During the visit, evaluation of tolerance and compliance to the current regimen should be noted. Poor compliance might be improved with combination products. Excessive dryness or irritation may be improved by lowering the concentration of a product, changing the base from a more drying one, such as a gel or solution, and using a more hydrating base such as a cream, or reducing frequency of application.

Long-term maintenance outcomes have been minimally studied, but **general consensus is that oral medications, except for possibly oral contraceptives, have a finite treatment time**. Topical medication should be introduced once the disease is sustainably under control. Because **topical retinoids** act on the microcomedone, they are **popular preventive products** and are often used for **long-term maintenance**. Two trials support this, showing continued control of previously moderate to severe acne for 4 to 6 months after discontinuing systemic antibiotic therapy. (84)(85)

Postacne Scar Treatment

Lingering signs of acne lesions are common and can be distressing. Several techniques try to ameliorate the appearance of acne scars, but most split-face studies have unpredictable results, resulting in no gold standard as of yet.

Cosmetic camouflage helps with erythema, postinflammatory dyspigmentation, and, to a more modest extent, atrophic scars. (86)(87) **Dermabrasion** is a mechanical technique whereby a motorized tool coated with an abrasive substance is used to remove the superficial layers of skin, creating a wound, and thereby encouraging healing and laying down of new collagen. Edema and erythema may persist for weeks after this intervention. (88) **Dermal fillers**, made of several materials but most commonly hyaluronic acid, can be injected into acne scars. These

procedures, most often used in the adult population, are an **expensive option** and must be **repeated every 6 to 9 months** to achieve a sustained effect. (89)

Subcision introduces a small needle into the periphery of an atrophic scar and is moved back and forth with the aim of releasing a tethered base. Subsequent bleeding is also thought to recruit new collagen formation, which can act as a filler to improve scar appearance. There are a few split-face randomized controlled trials that show efficacy and good tolerability of this technique, although these studies have small sample sizes. (90)(91)

Laser and Light Treatment

Laser and light therapies are 2 modalities sometimes used in acne management. Some are used **to reduce lesion count and erythema**, and others are better for treating **scarring**.

For active lesions, pulsed dye laser (PDL) is Food and Drug Administration (FDA) approved for inflammatory acne sequelae, although data are conflicting. (92) PDL is **most commonly used and indicated for vascular lesions**; its chromophore is hemoglobin. It targets the erythema of acne. (93)(94) Seaton et al (92) randomized 41 patients to receive PDL or a sham treatment once and assessed patients at 2-week intervals until 12 weeks after therapy. They noted a significant improvement in lesion count and erythema, but Orringer et al (95) noted no difference in their split-face study of 40 patients and could not definitively recommend PDL. A more recent 2017 blinded Thai study randomized 30 adolescents aged 13.0 to 21.6 years to receive a split-face treatment of 595-nm PDL versus no treatment. There was **no statistically significant decrease in acne erythema**, as in Orringer et al's study, **but the active papule count was significantly improved** on the PDL side after 4 weeks and there was high reported patient satisfaction. (96)

Light-based therapies (usually red and blue light) are thought to treat active acne through **reduction of *P. acnes*** levels by targeting their bacterial porphyrins. (97) Both red and blue may be helpful in decreasing inflammation and lesion count, but many trials looked at a very small number of participants without a control group. (98)(99) It seems that the improvement is likely only marginal, based on a 2016 Cochrane review. (101)

Laser treatment of acne scars is most commonly studied using fractional carbon dioxide lasers that penetrate only the epidermis and upper dermis, creating thermolysis and **encouraging growth of new collagen**. (100) There are many small, heterogeneous studies that support the use of fractional laser, and it may well be a promising option,

(102)(103) but patients should expect postprocedure edema and erythema, and practitioners should be wary of patient skin type because some may experience substantial post-inflammatory dyspigmentation.

Summary

- Acne vulgaris is a common problem in pediatric practice with important psychosocial consequences.
- Acne vulgaris is caused by the tetrad of inflammation, association with *Propionibacterium acnes*, abnormal keratinocyte shedding, and increased sebum production. Management aims to educate the patient; treat comedones, inflammatory papules, and pustules; and prevent scarring.
- There is high-quality evidence in randomized controlled and split-face trials that mild to moderate disease can be ameliorated with first-line topical therapies, including acids, benzoyl peroxide, topical antibiotics, and topical retinoids. (40)(41)(44)
- In women who can take the oral contraceptive pill and who experience premenstrual flares, especially along the jawline and lower face, we have presented 2 randomized controlled trials supporting use of the oral contraceptive pill. (59)(60)
- Severe disease warrants systemic treatment, including oral antibiotics (49) or isotretinoin; a low-dose or intermittent regimen with isotretinoin seems to have good efficacy and tolerability. We expect to see more studies addressing this topic in the near future. (65)(66)
- Based on consensus there is good evidence that topical retinoids are the treatment of choice for maintenance therapy. (79)(80)

- All medications have potential adverse effects, which should be discussed with the patient, and a trial of medication should be given an appropriate amount of time to exert its effects (ie, ≥ 6 weeks).
- Postacne sequelae can be treated with a variety of modalities, including peels, physical techniques, and lasers, although trials of these modalities are considered low quality due to lack of reproducibility and small study sizes.

To view teaching slides that accompany this article, visit <http://pedsinreview.aappublications.org/content/40/11/577.supplemental>.

Acne Vulgaris in the Pediatric Patient

Rosalind Ashton, MD, MSc*
Miriam Weinstein, MD, FRCP†

*King's College London School of Medical Education, St. John's Institute of Dermatology, London, England, United Kingdom
†The Hospital for Sick Children, Toronto, Ontario, Canada

Pediatrics in Review

American Academy of Pediatrics
DEDICATED TO THE HEALTH OF ALL CHILDREN

References for this article are at <http://pedsinreview.aappublications.org/content/40/11/577>.

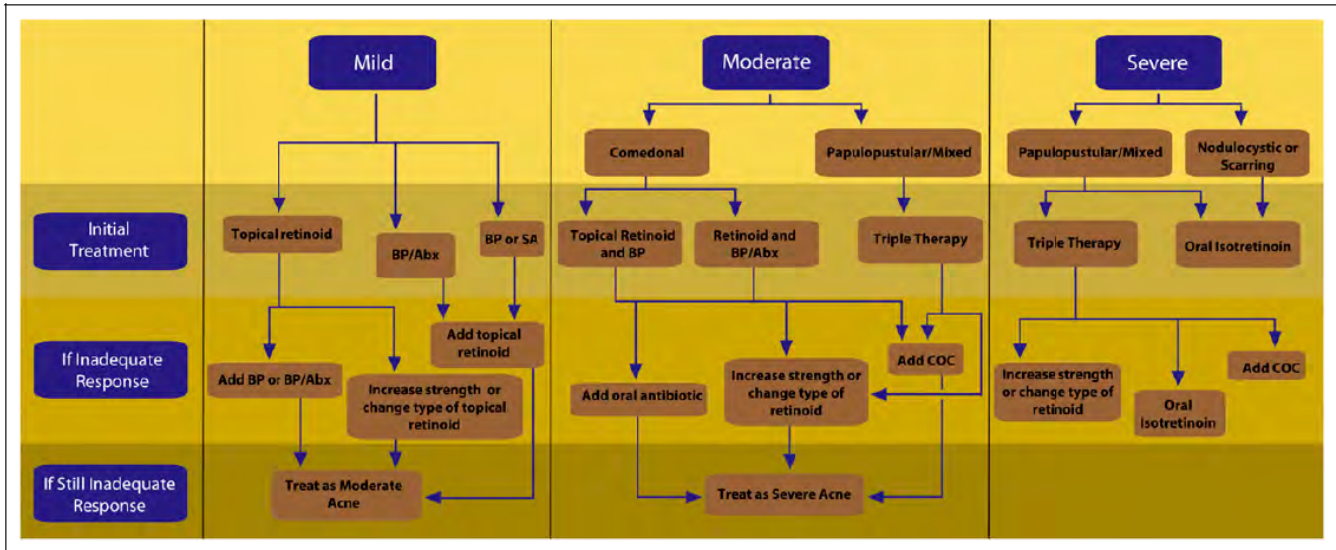


Figure 5. Treatment algorithm for adolescent acne. Triple therapy is benzoyl peroxide (BP), topical retinoid, and oral antibiotic. Abx=topical antibiotic (such as topical clindamycin or erythromycin); COC=combined oral contraceptive.

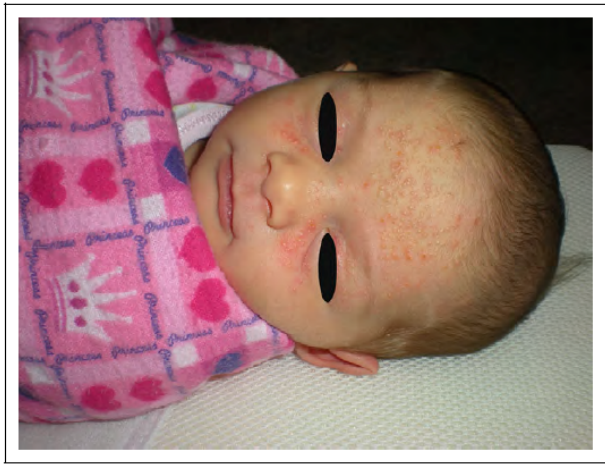

Figure 2. Neonatal acne.

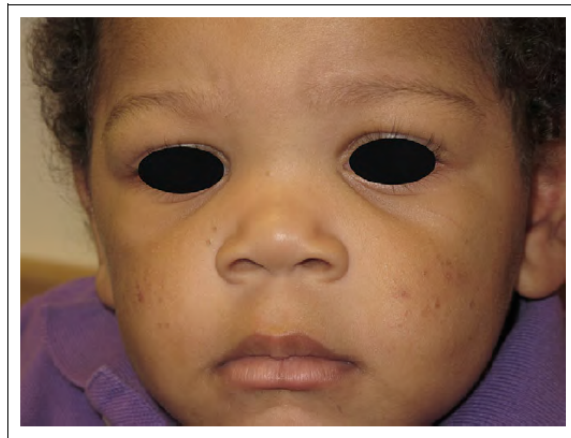

Figure 3. Infantile acne.

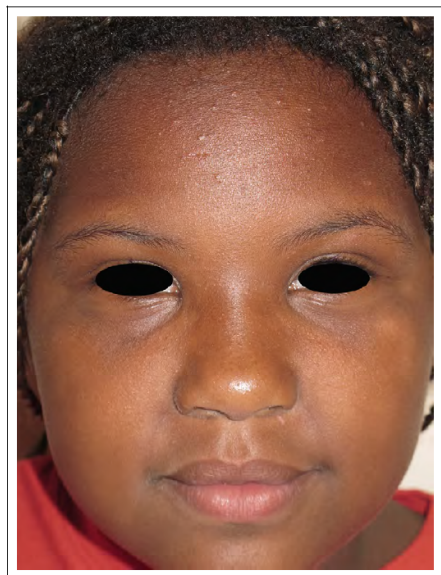

Figure 6. Mild acne.

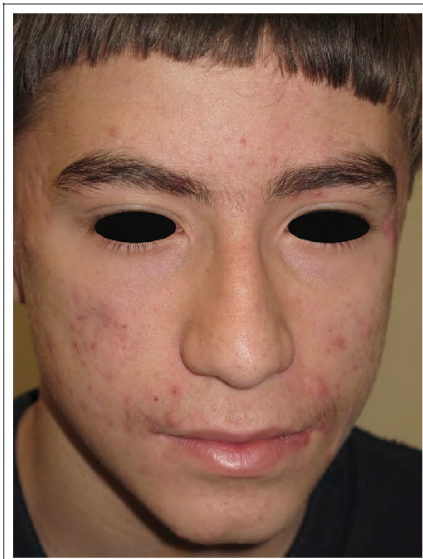

Figure 7. Moderate acne.

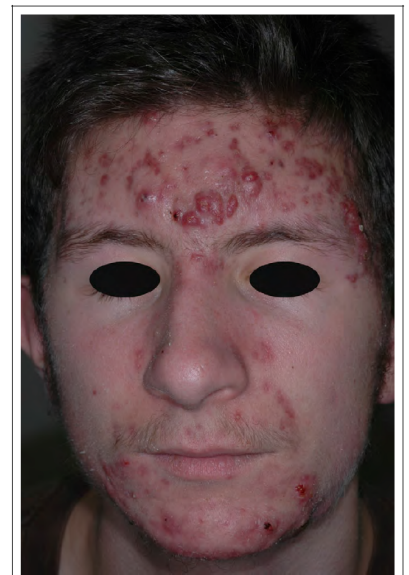
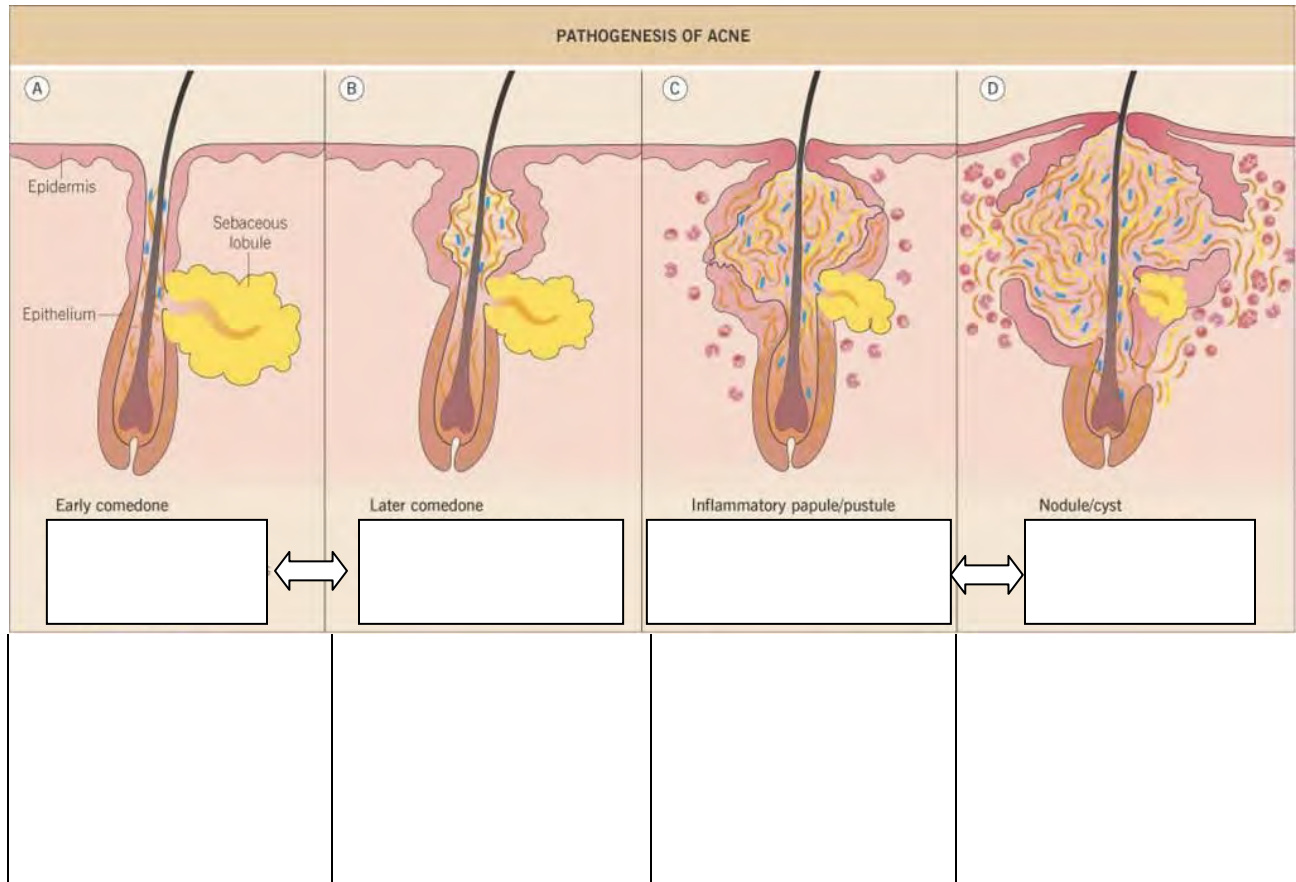


Figure 8. Severe acne.

Adolescent III Quiz:

- 1a. Complete the following diagram, using the **4 pathogenic processes** discussed in the article.
 1b. Indicate, in the table below, which **medications** address each component of the pathogenesis.



- 1c. Circle the medications that comprise **triple therapy**
 1d. Underline which of these medications **prevents antibiotic resistance**
 1e. Box which of these medications **improves penetration** of other topical therapies
 1f. Cross-out which of these medications *should not* be used as **monotherapy**

2. Acne is most common in adolescents, with _____ of teens/young adults affected. That said, please complete this chart comparing the other ages & stages of acne. In which of these stages is new-onset acne unusual? _____

	Neonatal	Infantile	Mid-Childhood	Pre-Adolescent
Age Range				
Appearance				
Cause				
Treatment				

Adolescent III Mega-Case:

15 year-old twins Jack and Jill present for routine sports physicals. Mom reports a concern about their acne “not going away” despite expensive OTC treatments. When you ask the twins about it, Jack just shrugs and Jill rolls her eyes and says “Mom, you are *so* embarrassing”. **What do you want to know about their acne?**

You interview Jack and Jill separately—and with their mother out of the room— so that you can also complete a HEADSS exam as part of your history. You find out the following:

Jack

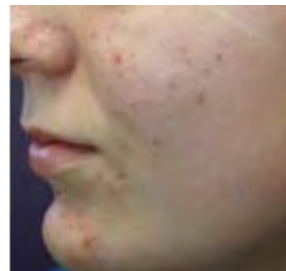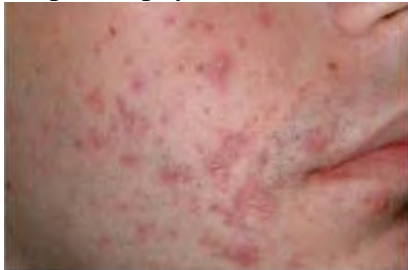- Has had acne since age 12
- Has tried Clearasil face wash, “sometimes”
- Denies other meds or drugs, including steroids
- h/o atopic dermatitis, for which he uses “some lotion”
- Competitive wrestler (wears headgear daily and can't remember the last time it was washed)
- Today is an “average skin day . . . it’s not really a big deal”

Jill

- Has had acne since age 11
- Has tried tea-tree oil, Neutrogena, Clean & Clear, and Proactiv. Intermittently compliant.
- Denies other meds or drugs, including steroids
- Uses MAC cosmetics (“I never go out without cover up and foundation”). Competitive dancer (“And I have to wear stage make-up for competitions”)
- Menses at age 13. “Irregular” (2-6 mo between periods, last 2-10 days, light to moderate flow). “Hooks up” (she defines as “everything but” intercourse). Not on OCPs.
- Today is a “bad skin day . . . a horrible, horrible day”.

What should you include on your physical exam?

You complete a physical exam on both twins, focusing on the skin. You observe the following:



Jack: 1/2 of the face involved. Many papules and pustules. No nodules. Multiple small pits and scars. Lesions on chest and back.

Jill: 1/4 of the face is involved (T-zone). Mostly blackheads and whiteheads. 1-2 papules. No lesions on chest and back.

What are the different types of presentations of adolescent acne?

How would you characterize the twins' acne?

Do you want to pursue any further evaluation? If so, what are your next steps?

What is your initial treatment for each?

How will you counsel Jack & Jill to use the topical products? Any side-effects?

If you decide to recommend a PO product, how will you counsel them to use it?

What are the benefits to the newer (and more expensive) combination products?

When should the twins see an effect? When do you want to follow up?

Jack and Jill pledge to follow your instructions and be patient with the results. 6 weeks later, you find them both on your schedule. Jill tells you, “Things are not getting any better, and we couldn’t wait any longer!” Jack reports that his acne worsened 3 weeks after your visit, and it has gotten only slightly better from baseline since then. Jill admits that she has more “good skin days” now, but she is distressed by her persistent break-outs. **Now what?**

Jack shows some interest in Accutane. **How will you counsel him?**

Adolescent III Board Review:

1. A 14-year-old boy requests treatment for his acne. He is using no medications and has no known drug allergies. Physical examination of the face reveals a few small inflammatory papules and numerous blackheads and whiteheads; there is no scarring. No acne lesions are present on the chest and back.

Of the following, the MOST appropriate treatment is

- A. benzoyl peroxide topically
- B. benzoyl peroxide topically and tetracycline orally
- C. benzoyl peroxide topically and tretinoin topically
- D. clindamycin topically
- E. tretinoin topically

2. A 16-year-old girl requests treatment for acne. She has used a nonprescription medication containing benzoyl peroxide without significant benefit. Physical examination reveals inflammatory lesions and open and closed comedones on the face and inflammatory lesions on the chest and back; there is no scarring. She has no known allergies to medications.

Of the following, the MOST appropriate treatment is

- A. benzoyl peroxide topically and tretinoin topically
- B. clindamycin topically
- C. doxycycline orally and tretinoin topically
- D. isotretinoin orally
- E. tretinoin topically